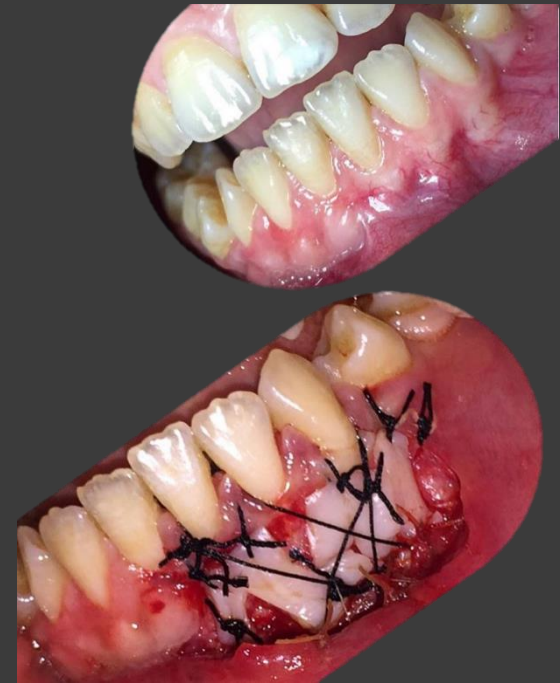



# MUCOGINGIVAL THERAPY –PERIODONTAL PLASTIC SURGERY

**DR.H.Gharati**

Periodontist & Dental Implant Specialist  
Assistant Professor, School Of Dentistry

# DEFINITION

- Friedman(1957):

*Mucogingival surgery* , Surgical procedures designed to preserve gingiva, remove aberrant frenulum or muscle attachments , and increase the depth of the vestibule.

- Miller (1993):

*Periodontal plastic surgery* , treatment of problems associated with the amount of gingivae and recession type defects to also include correction of ridge form and soft tissue esthetics.

- Glossary of terms in periodontology(2001):

*Mucogingival therapy* , involving procedures for correction of defects in morphology, position, and/or amount of soft tissue and underlying bone support at teeth and implants.

# PERIODONTAL PLASTIC SURGERY (WORKSHOP 1996 )

- Gingival augmentation
- Root coverage
- Correction of mucosal defects at implants
- Crown lengthening
- Gingival preservation at ectopic tooth eruption
- Removal of aberrant frenulum
- Prevention of ridge collapse associated with tooth ext.
- Augmentation of the edentulous ridge

# DEFINITION

- **Friedman(1957):**

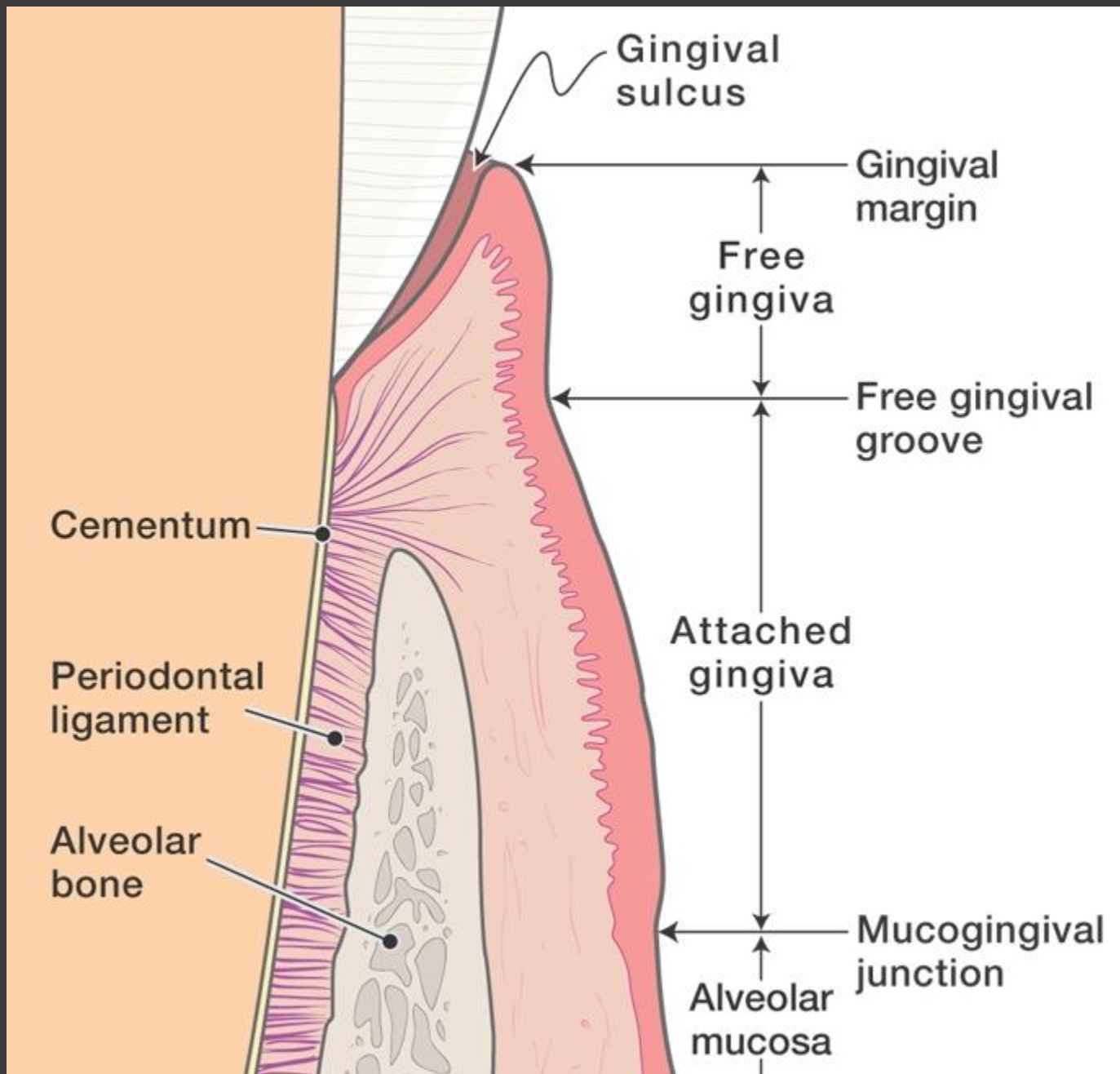
*Mucogingival surgery* , Surgical procedures designed to preserve gingiva, remove aberrant frenulum or muscle attachments , and increase the depth of the vestibule.

- **Miller (1993):**

*Periodontal plastic surgery* , treatment of problems associated with the amount of gingivae and recession type defects to also include correction of ridge form and soft tissue esthetics.

- **Glossary of terms in periodontology(2001):**

*Mucogingival therapy* , involving procedures for correction of defects in morphology, position, and/or amount of soft tissue and underlying bone support at teeth and implants.



# THE FIVE OBJECTIVES OF PERIODONTAL PLASTIC SURGERY

1. Problems associated with attached gingiva
2. Gingival dimensions and periodontal health
3. Marginal tissue recession
4. Problems associated with an aberrant frenum
5. Esthetic surgical therapy
5. Tissue engineering

# Gingival dimensions & periodontal health

Narrow zone of gingiva :

- (1) Insufficient to protect the periodontium from **injury** caused by friction forces encountered during mastication .
- (2) Insufficient to dissipate the **pull on the gingival margin** created by the muscles of the adjacent alveolar mucosa.
- (3) Facilitate **subgingival plaque formation** because of improper pocket closure resulting from the movability of the marginal tissue
- (4) Favor attachment loss and soft tissue recession because of **less tissue resistance** to apical spread of plaque-associated gingival lesions





- Some authors suggested that less than 1 mm of gingiva maybe sufficient (Bowers 1963).
- The apicocoronal height of keratinized tissue ought to exceed 3 mm (Corn 1962).
- An adequate amount of gingiva is any dimension of gingiva which:
  - (1) Is compatible with gingival health
  - (2) Prevents retraction of the gingival margin during movements of the alveolar mucosa(Friedman 1962; De Trey & Bernimoulin 1980).

# THE FIVE OBJECTIVES OF PERIODONTAL PLASTIC SURGERY

1. Problems associated with attached gingiva
2. Gingival dimensions and periodontal health
3. Marginal tissue recession
4. Problems associated with an aberrant frenum
5. Esthetic surgical therapy
5. Tissue engineering

# MARGINAL TISSUE RECESSION

population with  
standard oral hygiene



Buccal surfaces



All tooth surfaces

**prevalence and severity is more pronounced at single-rooted teeth than at molars**

# MARGINAL TISSUE RECESSION



## Definition

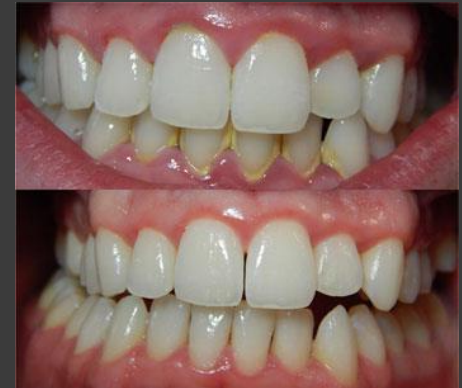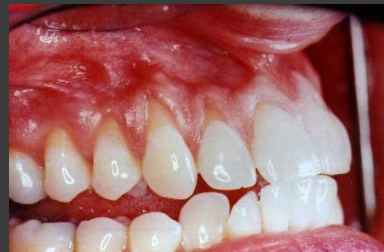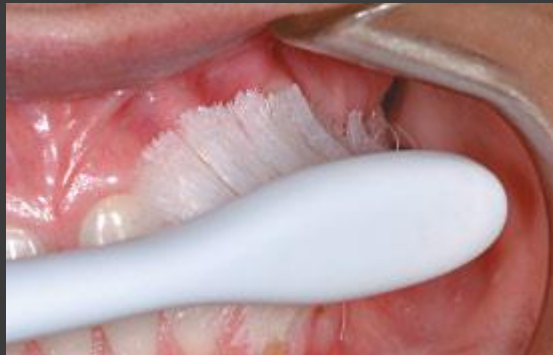Gingival recession is defined as location of the gingival margin apical to the cemento-enamel junction.

# LOCAL FACTORS ASSOCIATED WITH MARGINAL TISSUE RECESSION

- (1) Vigorous toothbrushing is a predominant causative.  
Particularly in young individuals.  
Use of hard toothbrushes.
- (2) Alveolar bone dehiscences.
- (3) High muscle attachment and frenal pull.
- (4) Plaque and calculus .
- (5) Iatrogenic factors related to restorative and periodontal treatment procedures.

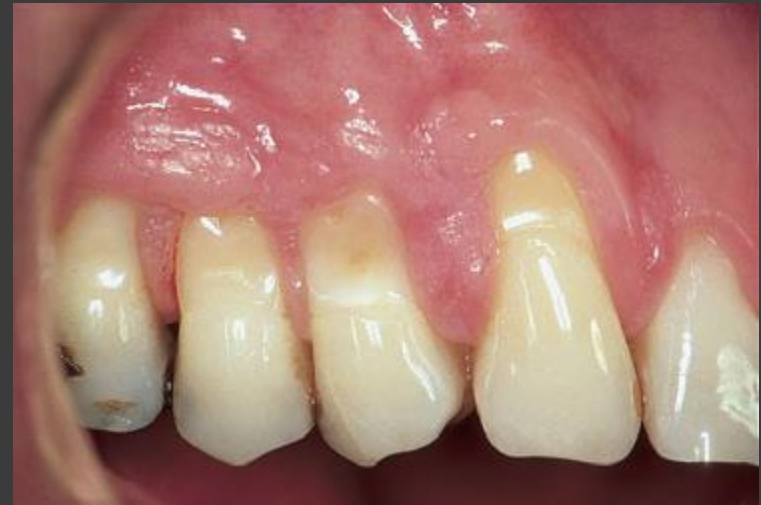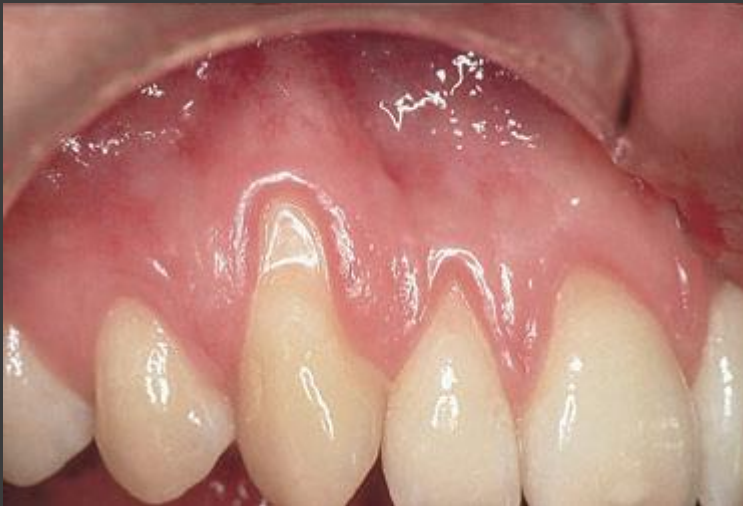# THREE DIFFERENT TYPES OF MARGINAL TISSUE RECESSIONS

- (1) *Recessions associated with **mechanical factors**, predominately toothbrushing trauma.*
- (2) *Recessions associated with localized **plaque-induced inflammatory lesions**.*
- (3) *Recessions associated with generalized forms of destructive **periodontal disease**.*



# RECESSIONS ASSOCIATED WITH MECHANICAL FACTORS

- Improper toothbrushing techniques.
- Often found at sites with clinically healthy gingiva.
- Exposed root has a wedged shaped defect.
- The surface of which is clean, smooth and polished.



# THE FIVE OBJECTIVES OF PERIODONTAL PLASTIC SURGERY

1. Problems associated with attached gingiva
2. Problems associated with a shallow vestibule
3. Problems associated with a paraded aberrant frenum
4. Minimal attached gingiva + adequate vestibular depth = not require surgical correction if proper atraumatic hygiene is practiced.
5. Minimal attached gingiva + no vestibular depth = mucogingival correction.



# THE FIVE OBJECTIVES OF PERIODONTAL PLASTIC SURGERY

1. Problems associated with attached gingiva
2. Problems associated with a shallow vestibule
3. Problems associated with an aberrant frenum
4. Esthetic surgical therapy
5. Tissue engineering

# INDICATIONS FOR GINGIVAL AUGMENTATION

1- Patient experiences **discomfort** during tooth-brushing and/or chewing due to an interfering lining mucosa.

**Presence of a narrow zone of gingiva cannot justify**

2- When **orthodontic tooth movement** is planned and the final positioning of the tooth can be expected to result in an alveolar bone dehiscence.  
(Proceedings of the 1st European Workshop on Periodontology 1994)  
(Proceedings of the World Workshop in Periodontics 1996)

3- Minimal amounts of keratinized attached gingiva with **no vestibular depth**.

4- When subgingival restorations are placed in areas with a **thin marginal** tissue.

# Techniques To Increase Attached Gingiva

## *A - Gingival augmentation apical to the area of recession*

- Grafts placed on a recipient bed apical to the recessed gingival margin.
- No attempt is made to cover the denuded root surface.

## *B - Gingival augmentation coronal to the recession (root coverage)*

- A graft is placed covering the denuded root surface.

**Both techniques widening of attached gingiva, enhance oral hygiene procedures, but only the latter can correct an esthetic problem.**

# Gingival Augmentation Apical To The Area Of Recession

- 1- Vestibular/gingival extension procedures
- 2- Free Gingival Autografts
- 3- Free connective tissue autografts
- 4- Apically positioned flap.

# Vestibular/Gingival Extension Procedures

## 1- Denudation Techniques

(Ochsenbein 1960; Corn 1962; Wilderman 1964)

## 2- Periosteal Retention or Split Flap Procedure

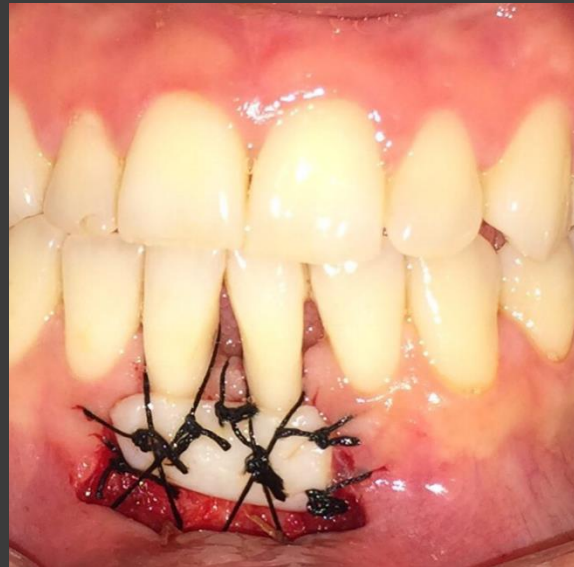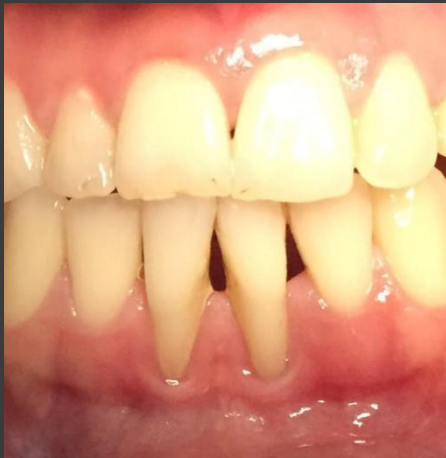(Staffileno 1962, 1966; Wilderman 1963; Pfeifer 1965)

# Gingival Augmentation Apical To The Area Of Recession

- 1- Vestibular/gingival extension procedures
- 2- Free Gingival Autografts
- 3- Free connective tissue autografts
- 4- Apically positioned flap.

# Free Gingival Graft Indication

- Increase gingival width
- Deepen vestibule
- Ridge augmentation



## **Advantages :**

- Donor material readily available, even with thin palates
- Predictable healing

## **Disadvantages :**

- Two surgical sites
- Color may not match recipient area
- Graft may be overly thick when mature
- More sensitivity from donor site
- The lack of predictability in attempting root coverage and the compromise blood supply to the graft must be mentioned.



## Free Gingival Autograft

- The Classic Technique(Bjorn 1963)
- Accordion Technique (Rateitschak 1985)
- Strip Technique (Han, Carranza Jr., and Takei, 1993)
- Combination Technique

# The Classic Technique

***Step 1:*** Pocket elimination

***Step 2:*** Recipient site preparation

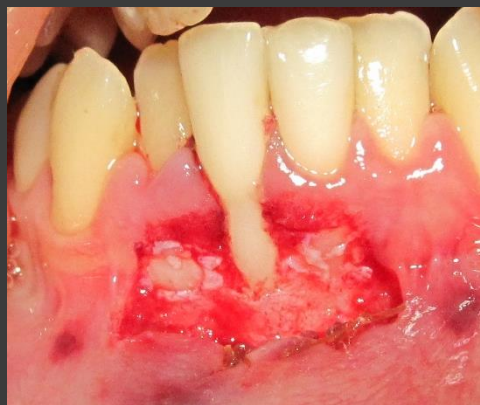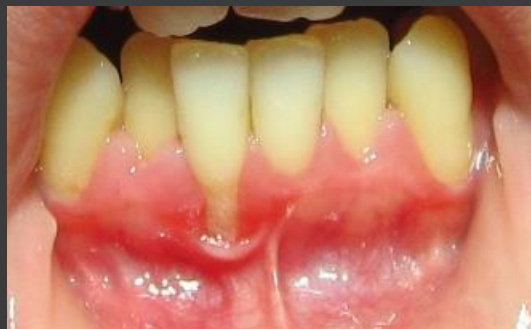***Step 3:*** Graft harvesting from the donor site

***Step 4:*** Transferring and immobilization of the graft

***Step 5:*** Donor site protection.

## *Step 2 : Prepare the Recipient Site*

- Extend the incisions to approximately **twice** the desired width of the attached gingiva, allowing for **50%contraction** of the graft when healing is complete.
- The amount of contraction depends on the extent to which the recipient site penetrates the muscle attachments.
- **Primary contraction**  $\longrightarrow$  amount of elastic fibers.  
**Secondary shrinkage**  $\longrightarrow$  cicatrization which binds the graft to the underlying bed. (Orban, 1966).

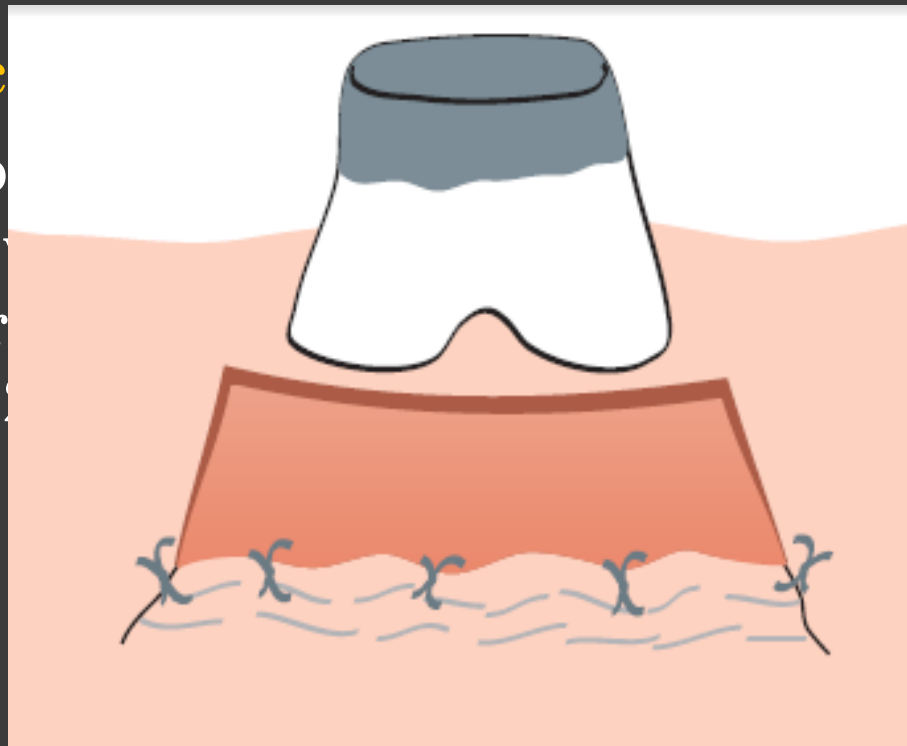


- Suture the flap where the apical portion of the free graft will be located. Three to four independent gut sutures are placed.
- aluminum foil template of the recipient site can be made.



### Grafts c

- 1-Less p
- 2-Less s
- 3-Better
- 4-1.5 to



### one tissue :

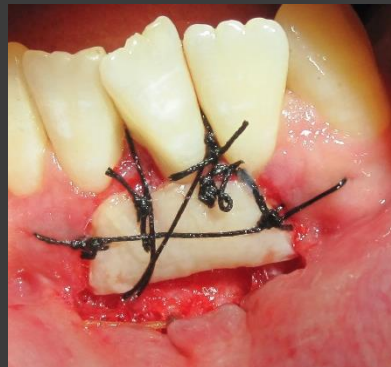raft.

### *Step 3 : Graft harvesting from the donor site*

- The palate is the usual site from which the donor tissue (premolars).
- The graft should consist of epithelium and a thin layer of underlying connective tissue.
- Placing sutures at the margins of the graft helps control it during separation and transfer.
- The ideal thickness of a graft is between **1.0 and 1.5 mm**.
- Graft separated mesiodistally.
- The graft is trimmed of all the fat and glandular tissue.
- The fat and glandular tissue inhibit the graft take by reducing plasmatic diffusion.
- Thin the edge to avoid bulbous marginal and interdental contours.

## Step 4 : Transferring and immobilization of the graft

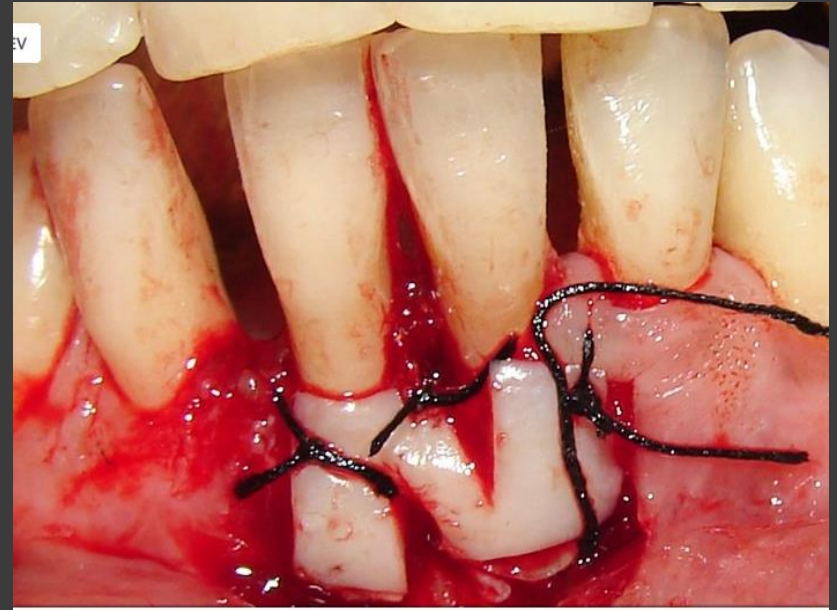
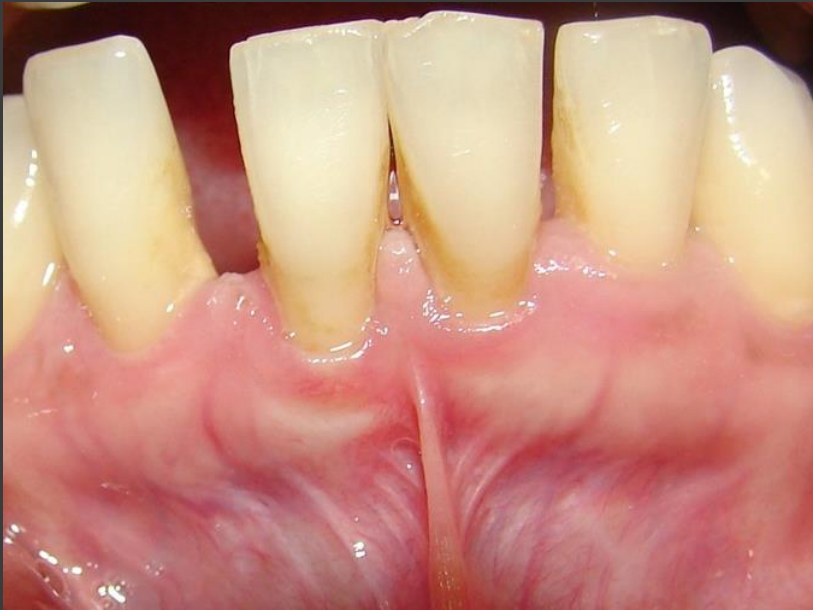- Remove the sponge from the recipient site; reapply it with pressure if necessary until bleeding is stopped.
- A thick clot interferes with vascularization.
- A space between the graft and the underlying tissue (dead space) impairs vascularization and jeopardizes the graft. (after suturing pressure against the graft for 5 min)
- Suture the graft at the lateral borders and to the periosteum to secure it in position.
- Horizontal stretching suture should be used to overcome the effects of primary contraction.
- This stretching suture allows the blood vessels within the graft to open, and permit diffusion of fluid.



- *Step 5 : Protect the donor site*
- Cover the donor site with a periodontal pack for 1 week.
- If Interdental spaces is available the pack may be retained by locking it through the interproximal spaces.
- A modified Hawley retainer is useful to cover the pack on the palate and over edentulous ridges.

# Accordion Technique

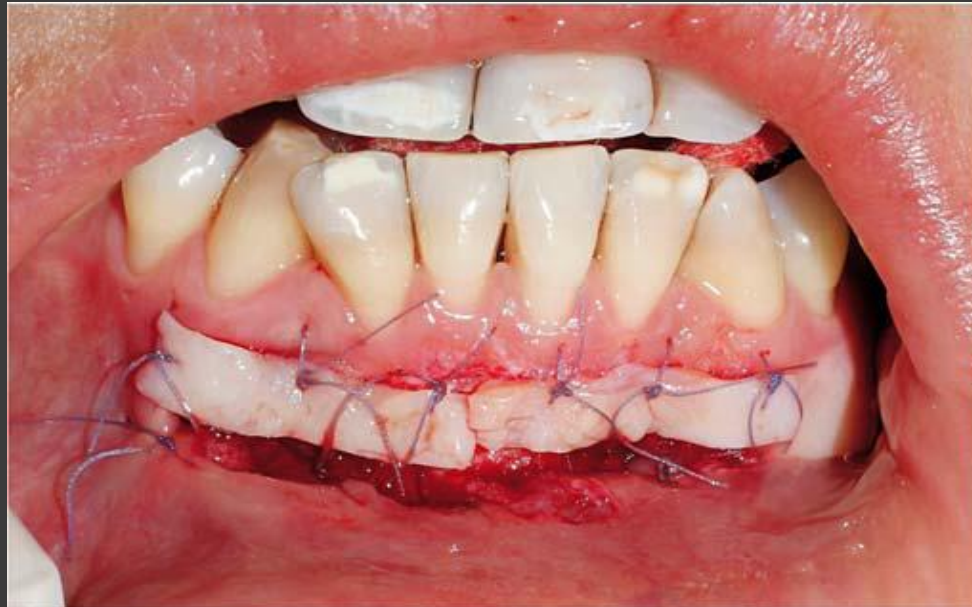- Described by Rateitschak (1985)
- Attains expansion of the graft by alternate incisions in opposite sides of the graft.
- This technique increases the donor graft tissue by changing the configuration of the tissue.



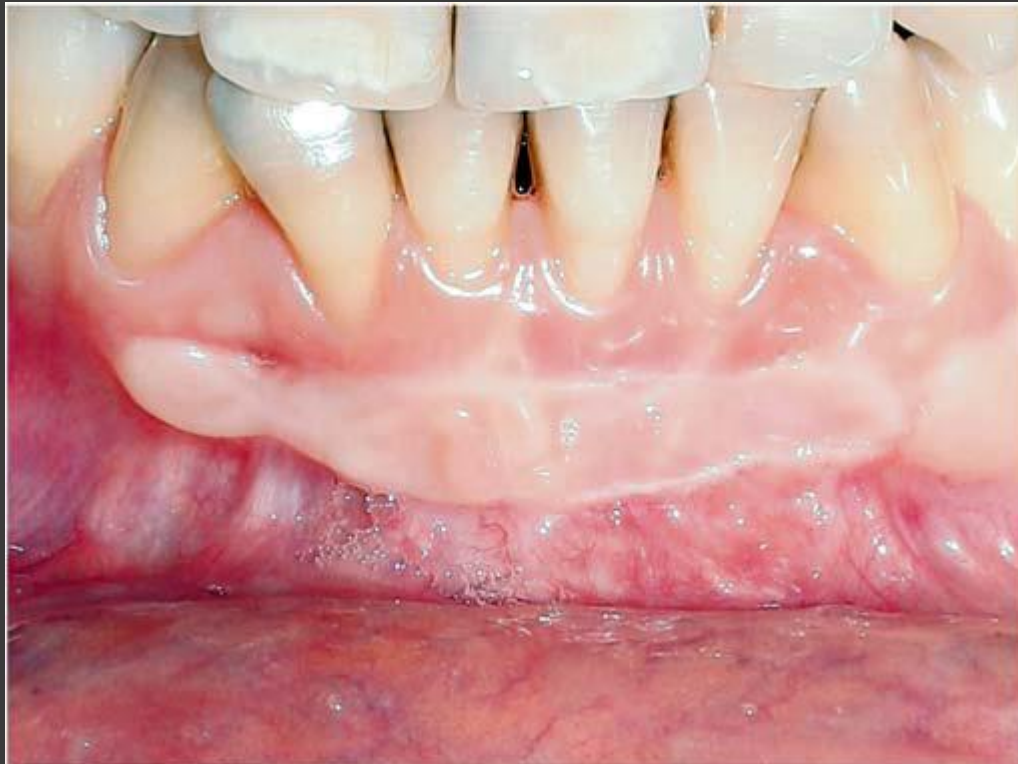

# STRIP TECHNIQUE

- Consists of two or three strips of gingival donor tissue about **3 to 5 mm wide** and long enough to cover the entire length of the recipient site.
- These strips are placed side by side to form one donor tissue and sutured on the recipient site.



- This technique is to alleviate large donor site and facilitate healing in the donor site (rapid healing).
- Greater shrinkage is expected in the graft.
- The donor site usually does not require suturing and heals uneventfully in 1 to 2 weeks.

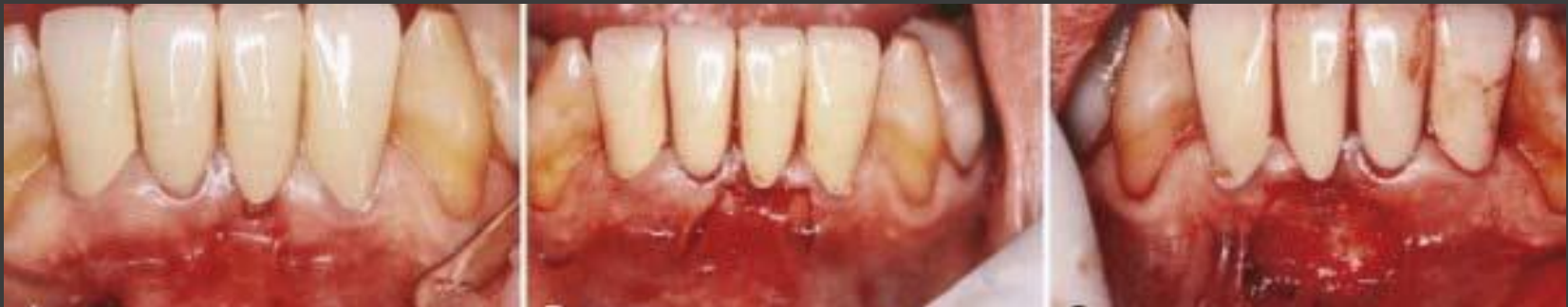

# Gingival Augmentation Apical To The Area Of Recession

- 1- Vestibular/gingival extension procedures
- 2- Free Gingival Autografts
- 3- Free connective tissue autografts
- 4- Apically positioned flap.

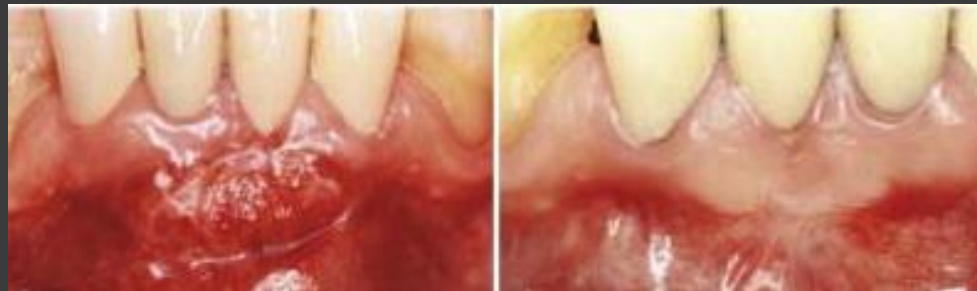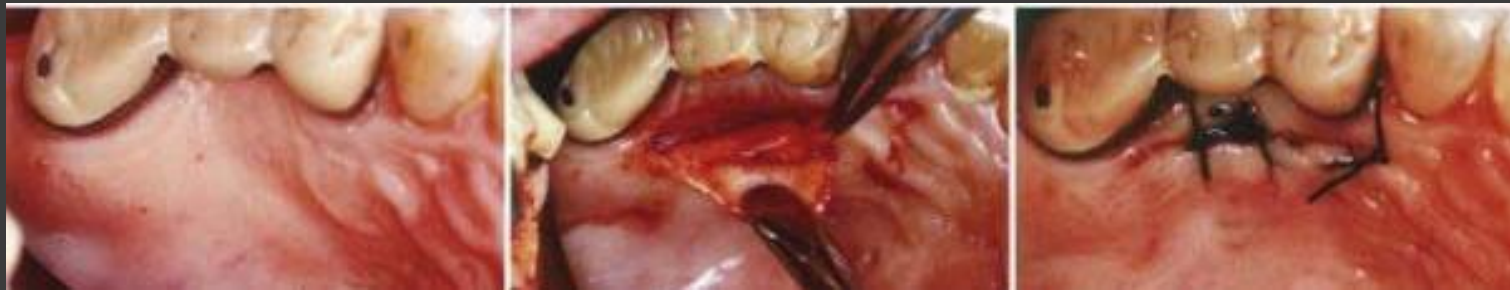# Free Connective Tissue Autografts

- Originally described by Edel (1974)
- Connective tissue carries the genetic message for the overlying epithelium to become keratinized.
- Only connective tissue from beneath a keratinized zone can be used as a graft.



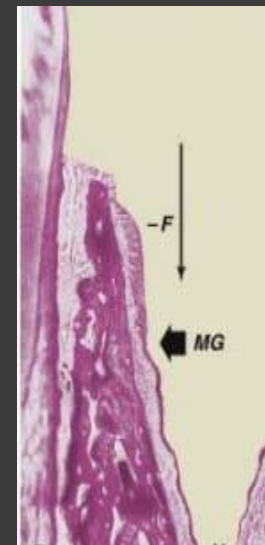
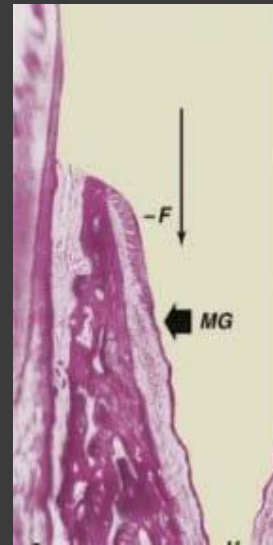
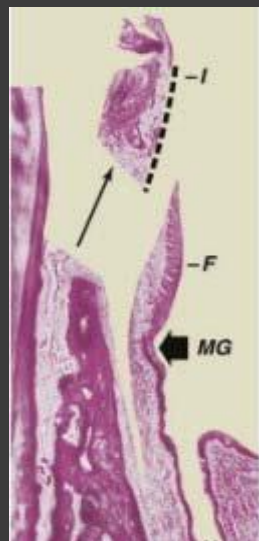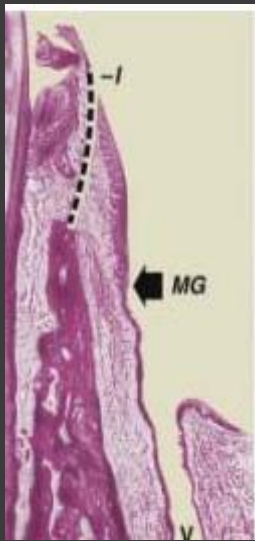
## Advantages :

- 1-Donor tissue is obtained from the undersurface of the palatal flap, which is sutured back in primary closure; therefore healing is by first intention.
- 2-The patient has less discomfort postoperatively at the donor site.
- 3-Improved esthetics because of a better color match



# APICALLY POSITIONED FLAP

- Friedman (1962)
- Partial thickness or full thickness
- Increases the width of the keratinized gingiva but cannot predictably deepen the vestibule.
- Adequate vestibular depth must be present before the surgery





# Periodontal Soft Tissue Non–Root Coverage Procedures: A Consensus Report From the AAP Regeneration Workshop

E. Todd Scheyer,<sup>\*</sup> Mariano Sanz,<sup>†</sup> Serge Dibart,<sup>‡</sup> Henry Greenwell,<sup>§</sup> Vanchit John,<sup>||</sup> David M. Kim,<sup>¶</sup> Lauren Langer,<sup>#</sup> Rodrigo Neiva,<sup>\*\*</sup> and Giulio Rasperini<sup>††</sup>



## CLINICAL QUESTIONS

### *Is There a Need for a Minimum Amount of Keratinized Tissue (KT)?*

Under optimal plaque-control conditions resulting in the absence of clinical inflammation, there is no need for a minimum amount of KT for preventing attachment loss (AL).

### *Which Clinical Scenarios Require a Minimum Amount of KT?*

- In the presence of **suboptimal plaque control** and clinical inflammation, AL and recession may result unless there is a minimum amount of KT. A minimum amount of **2 mm of KT with 1 mm of attached gingiva** has been recommended under these circumstances.
- In presence of **subgingival restorative margins** or **clasps** from removable appliances, specific **orthodontic tooth movement**.

J Periodontol • February 2015 (Suppl.)

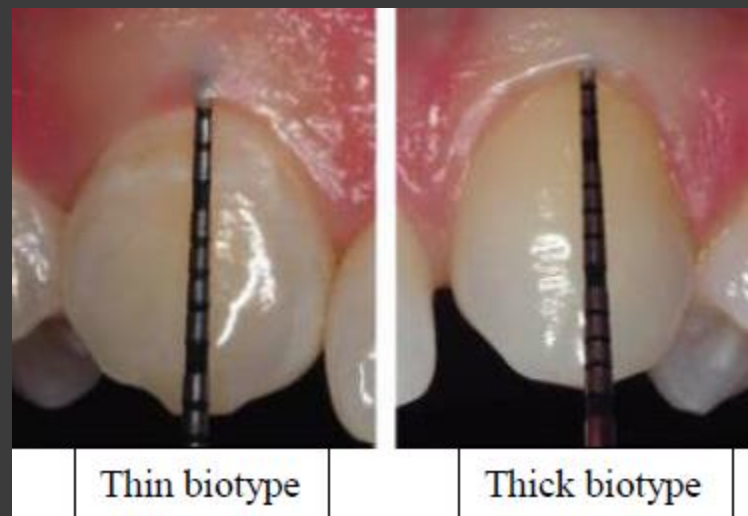
#### Periodontal Soft Tissue Non-Root Coverage Procedures: A Consensus Report From the AAP Regeneration Workshop

E. Todd Scheyer,\* Mariano Sanz,† Serge Dibart,‡ Henry Greenwell,§ Vanchit John,|| David M. Kim,¶ Laureen Langer,‡ Rodrigo Neiva,\*\* and Giulio Rasperini!†

## *How Relevant is the Recipient Site Periodontal Biotype?*

There is a general assumption that individuals with a **thin** periodontal **biotype**, which will include not only soft tissue thickness but also bone thickness and tooth position, will be **more prone to recession**.

Although there is consensus on the need for a minimum tissue thickness, there is no evidence defining this thickness.



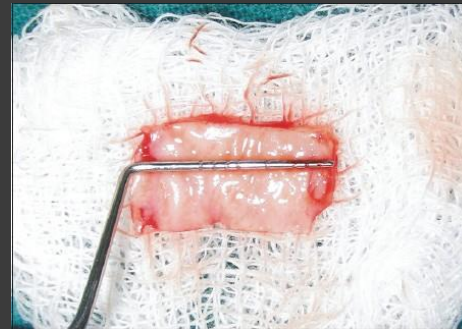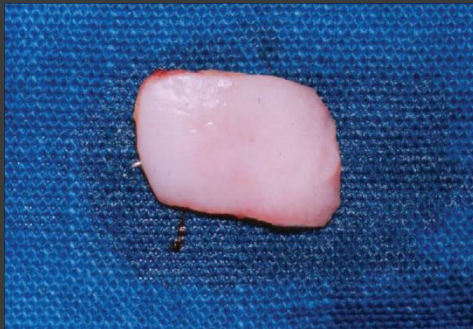## *Is There a Standard Procedure for KT Augmentation?*

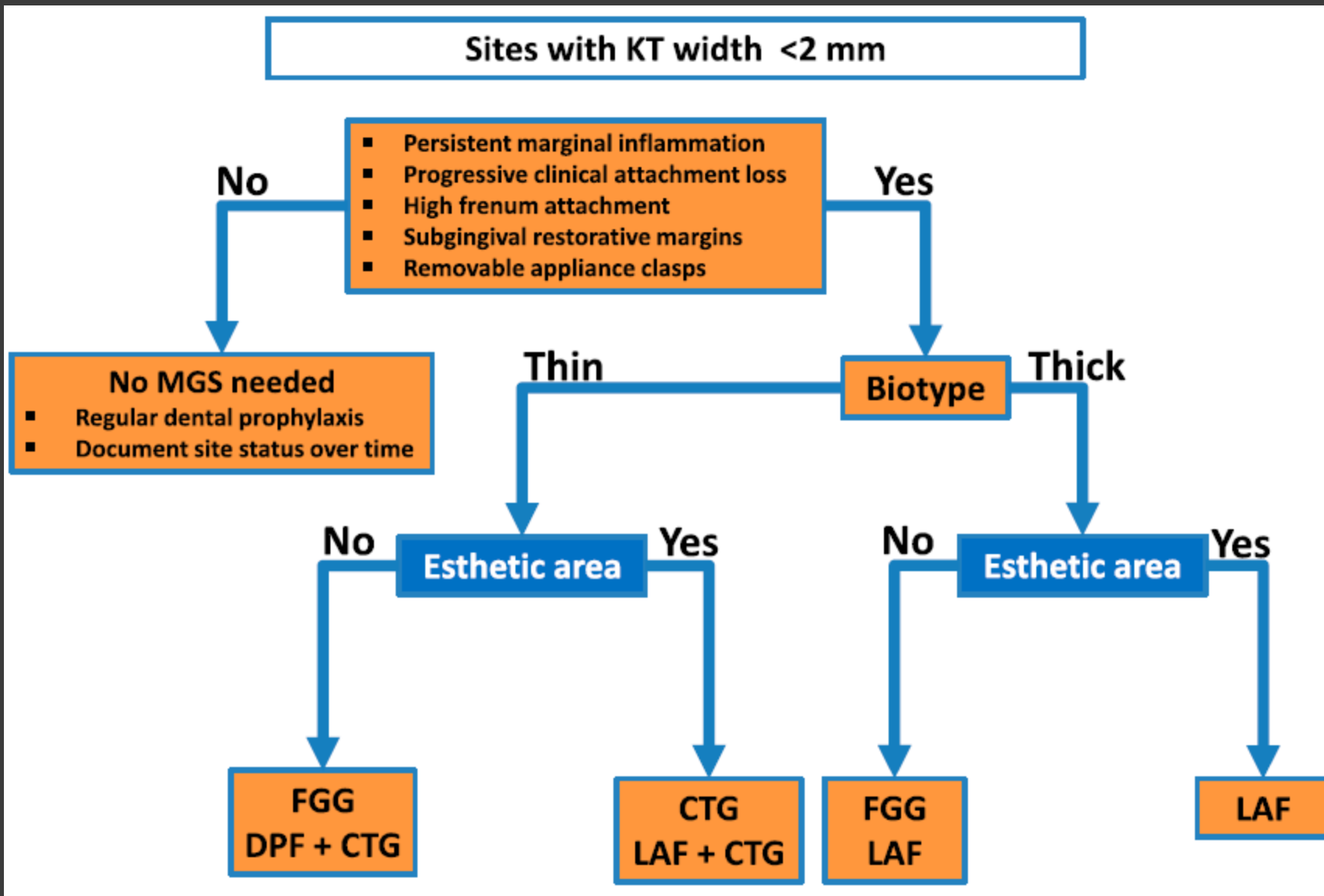
In situations in which gingival augmentation is indicated, autogenous gingival grafts have been considered to be the method of choice.

## *How Relevant is Graft Thickness?*

the minimum thickness of a gingival graft should range from **0.75 to 1.25** mm to ensure that the graft will have an adequate amount of connective tissue to allow for graft survival.

Thick grafts will have more primary contraction but less secondary shrinkage and less blending with adjacent tissues.





. MGS = mucogingival surgery; DPF = double papilla flap; LAF = laterally advanced flap.

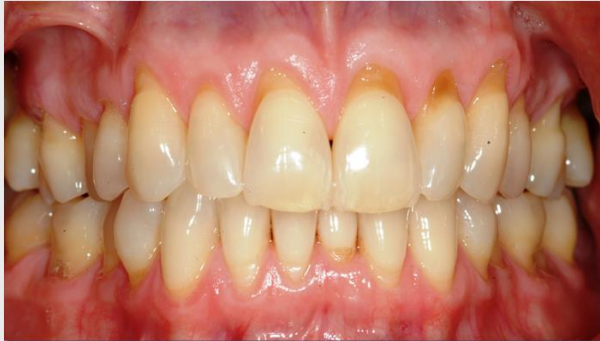# Techniques To Increase Attached Gingiva

*A - Gingival augmentation apical to the area of recession*

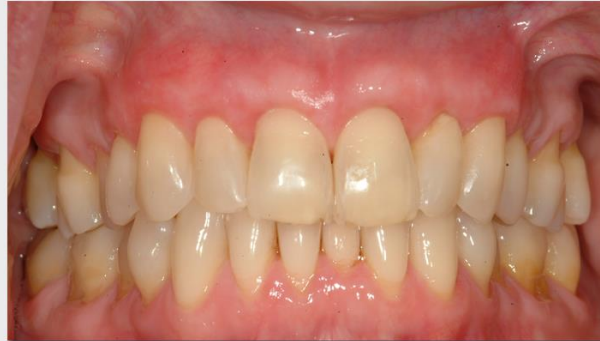*B - Gingival augmentation coronal to the recession (root coverage)*

# Root Coverage

- The main indications :
  1. Esthetic/cosmetic demands
  2. Root sensitivity
  3. Changing the topography of the marginal soft tissue in order to facilitate plaque control



***Before***



***After***

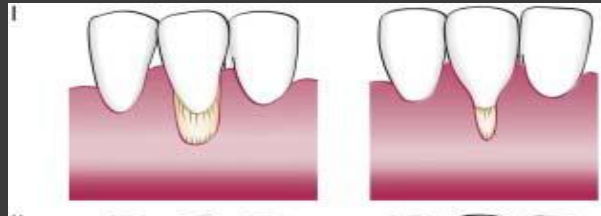# Classifications Of Denuded Roots

- Sullivan and Atkins(1960):

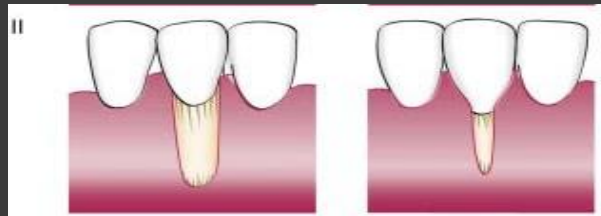
1-shallow-narrow 2-shallow-wide 3- deep-narrow 4- deep-wide.

- Miller (1985):

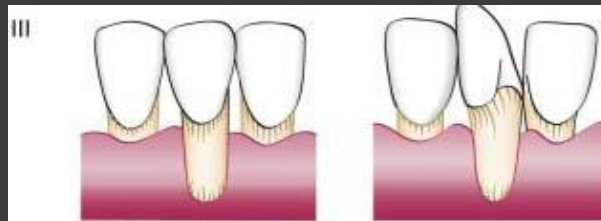
- *Class I.*



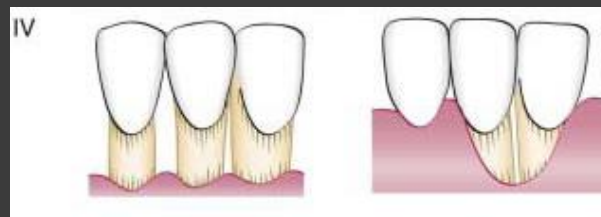
- *Class II.*

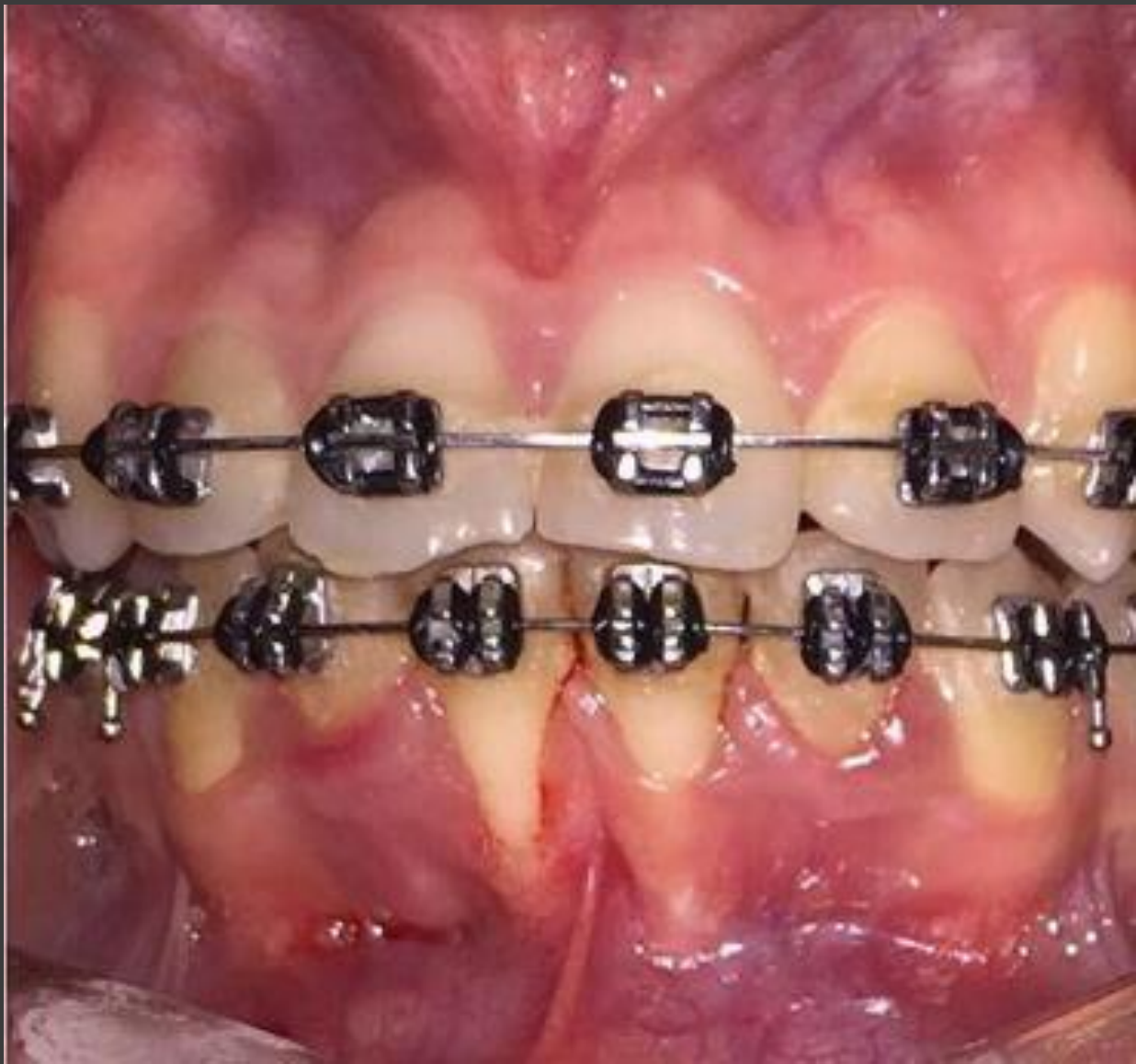

- *Class III.*

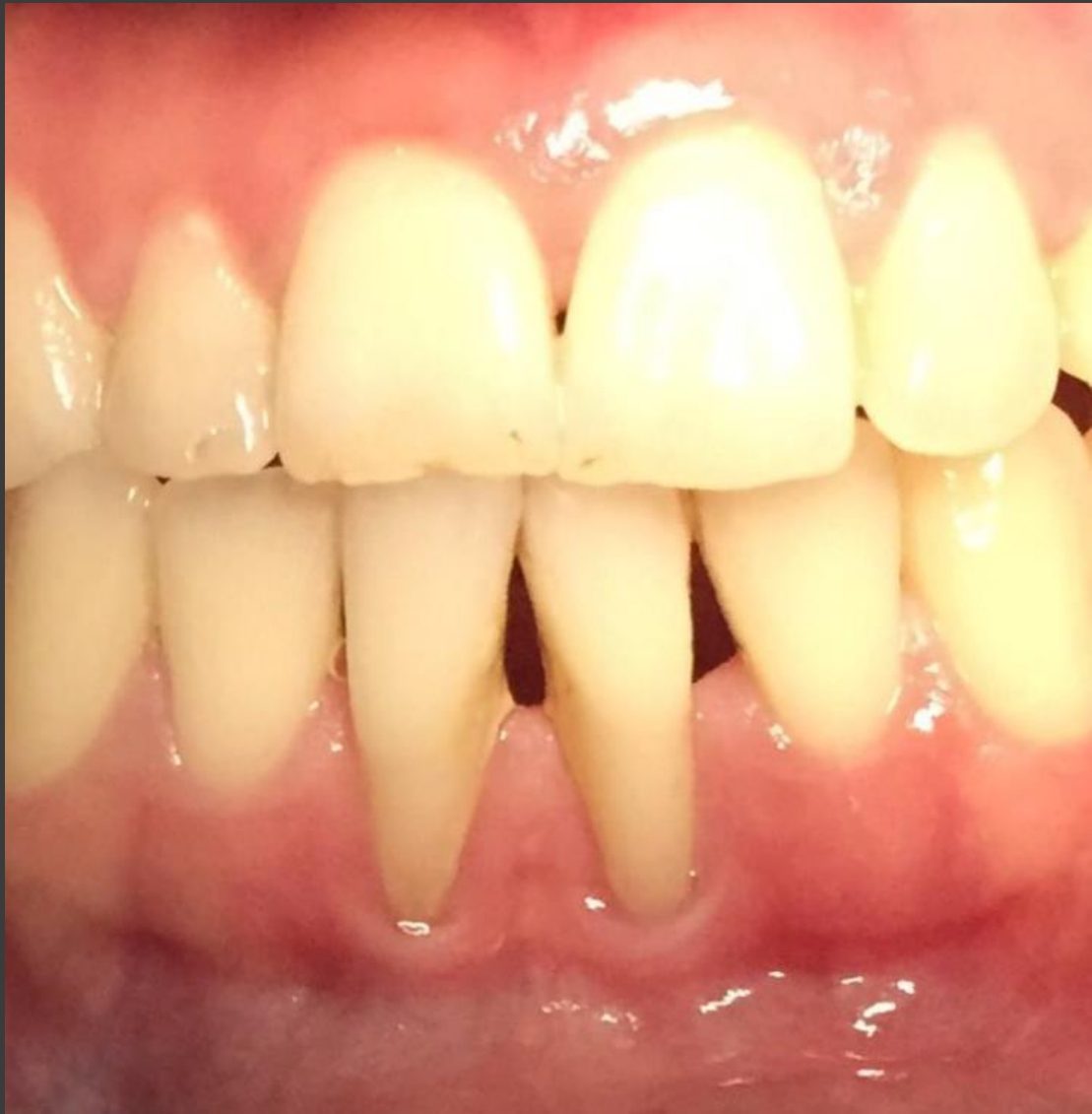

- *Class IV.*





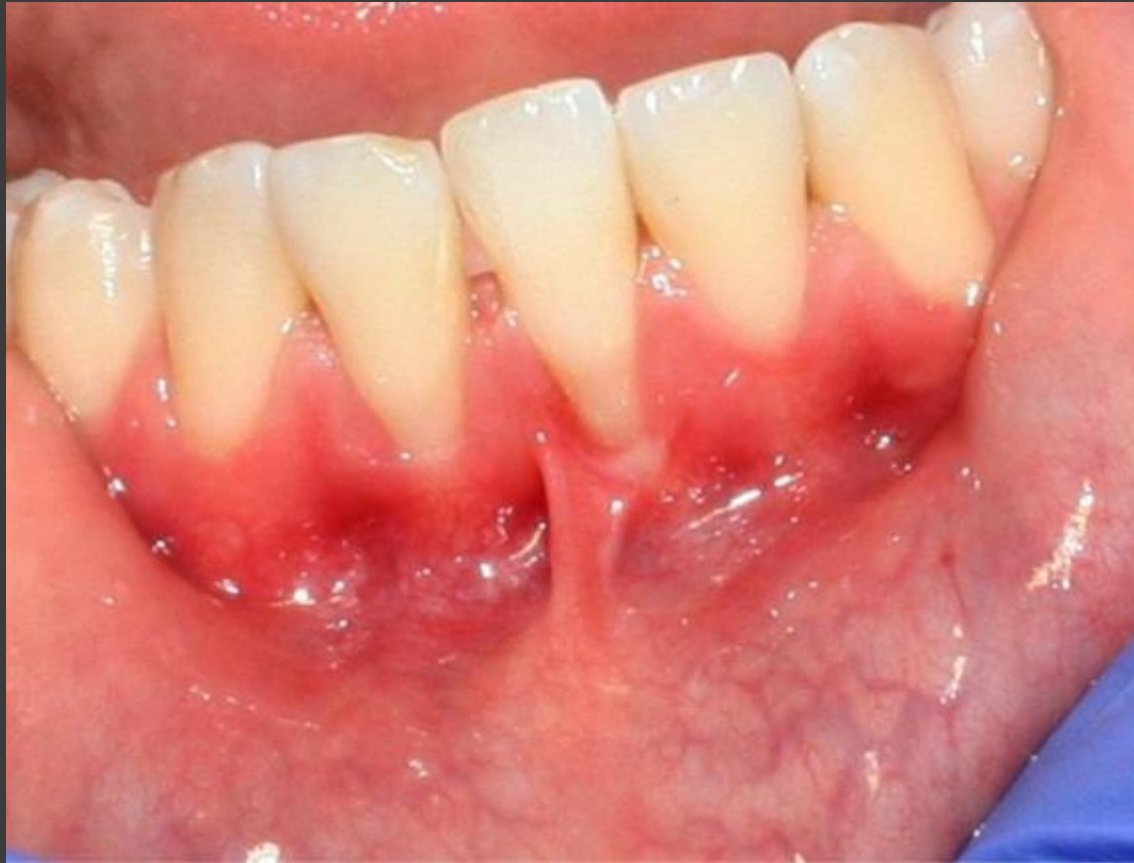



# Cairo et. al. Classified Gingival Recession

Class	Criteria
Recession Type 1 (RT1)	Gingival recession with no loss of interproximal attachment. Interproximal CEJ was clinically not detectable at both mesial and distal aspects of the tooth
Recession Type 2 (RT2)	Gingival recession associated with loss of interproximal attachment. The amount of interproximal attachment loss (measured from the interproximal CEJ to the depth of the interproximal pocket) was less than or equal to the buccal attachment loss (measured from the buccal CEJ to the depth of the buccal pocket)
Recession Type 3 (RT3)	Gingival recession associated with loss of interproximal attachment. The amount of interproximal attachment loss (measured from the interproximal CEJ to the depth of the pocket) was higher than the buccal attachment loss (measured from the buccal CEJ to the depth of the buccal pocket)

Table 4: Classification of gingival recession based on the assessment of CAL at buccal and interproximal sites<sup>12</sup>

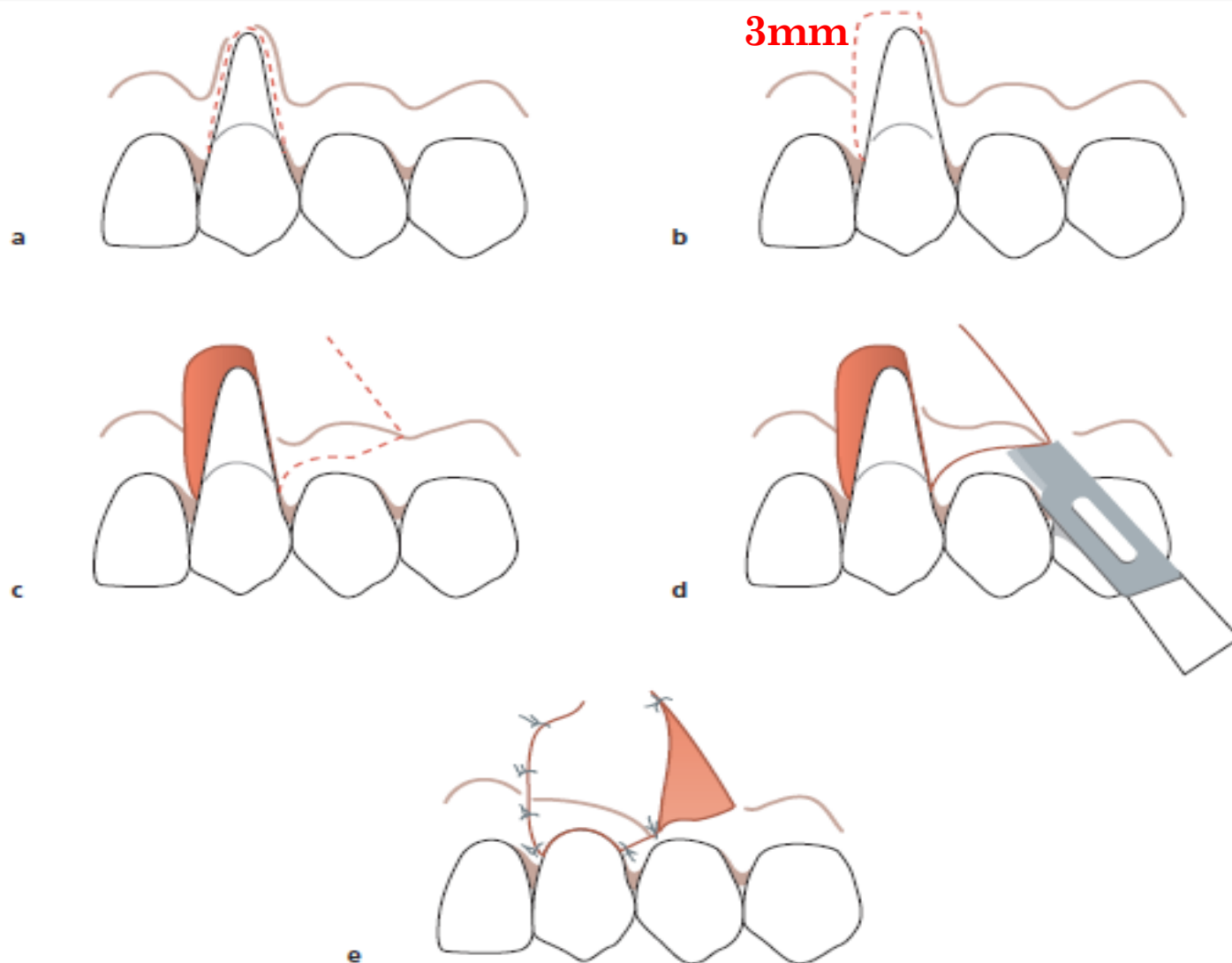


*Class III*

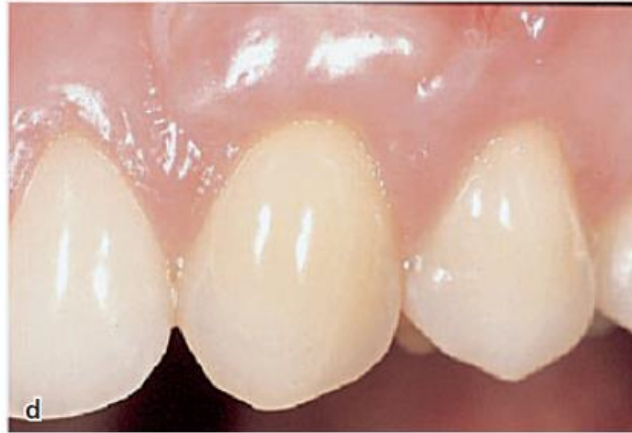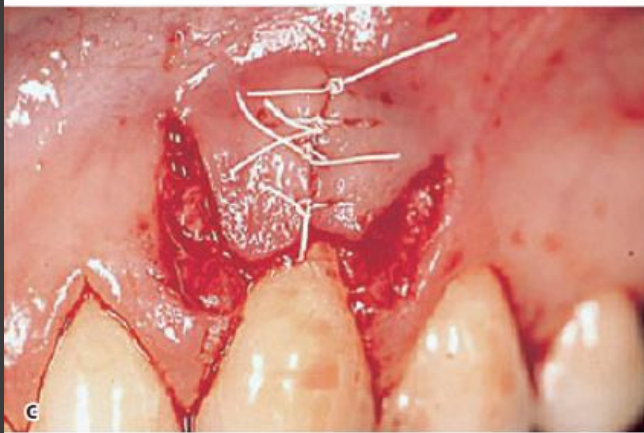
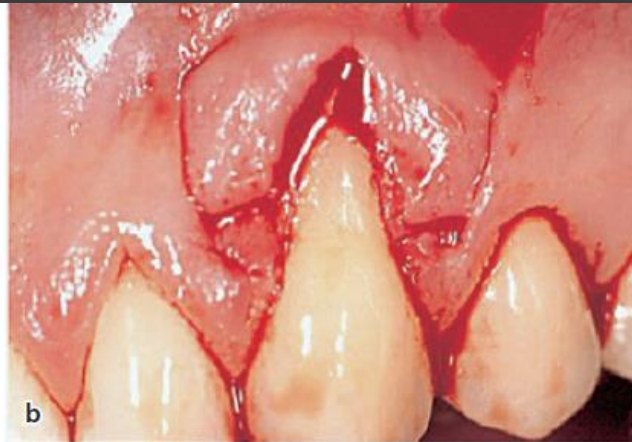
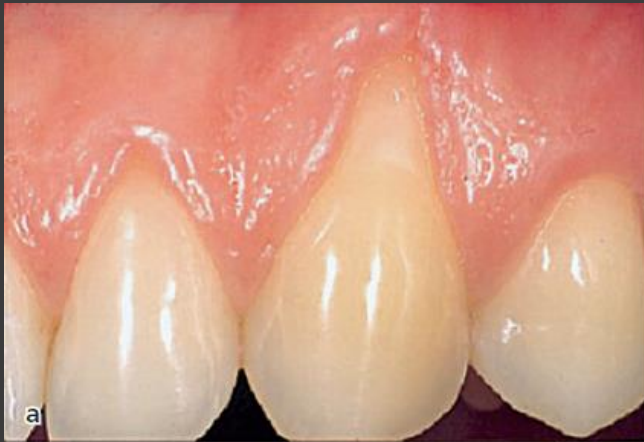# Techniques For Root Coverage

- *Pedicle soft tissue graft procedures*
- depending on the direction of transfer:
  - (1) *rotational flap procedures (e.g. laterally sliding flap, double papilla flap, oblique rotated flap)*
  - (2) *advanced flap procedures (e.g. coronally repositioned flap, semilunar coronally repositioned flap).*
- *Free soft tissue graft procedures.*
  - (1) epithelialized graft
  - (2) subepithelial connective tissue graft (nonepithelialized graft).

# Rotational Flap Procedure



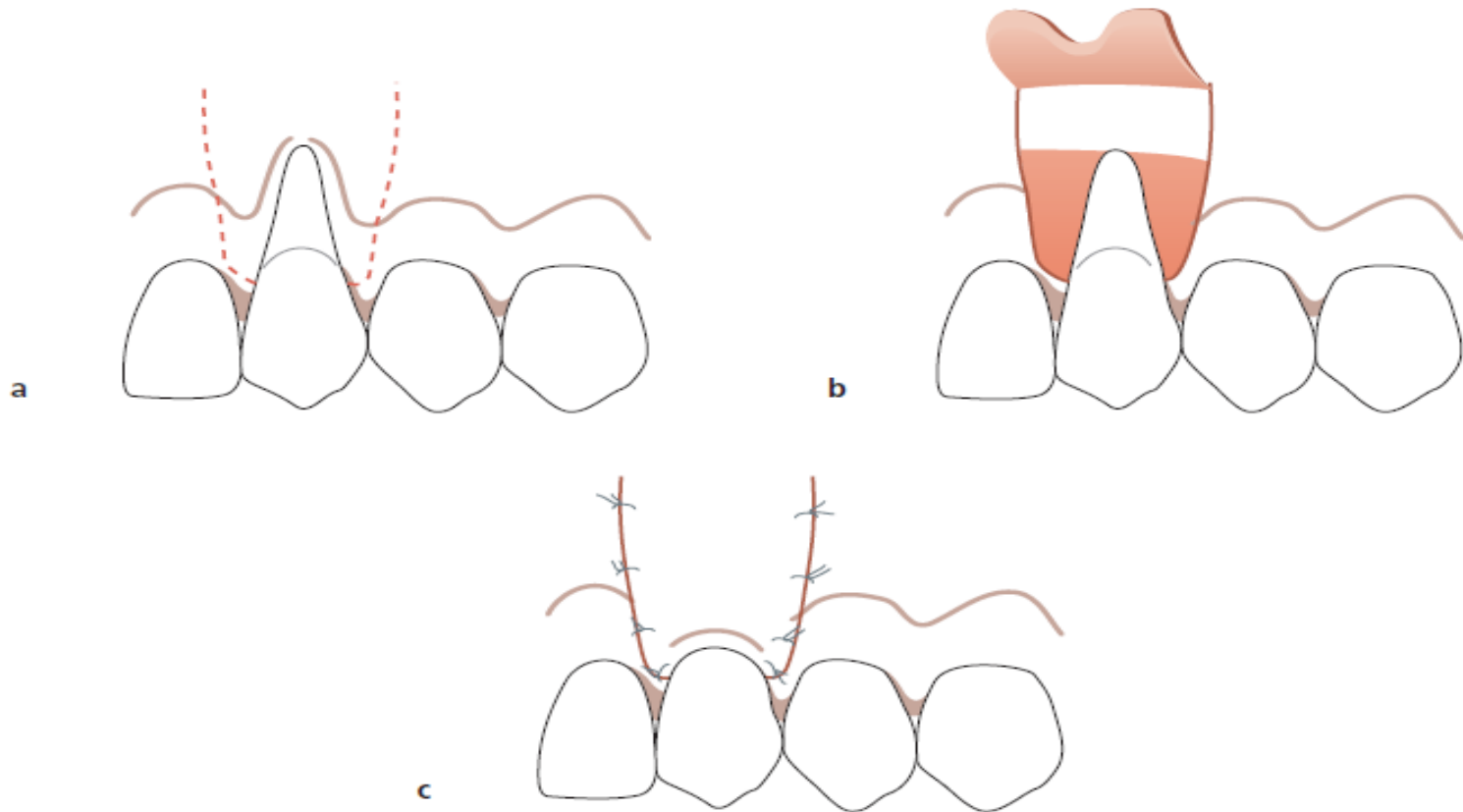
# Double Papilla Flap Procedure



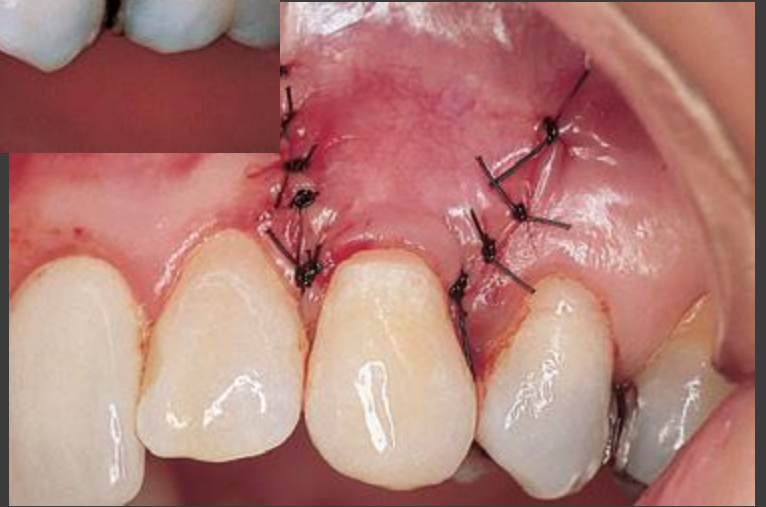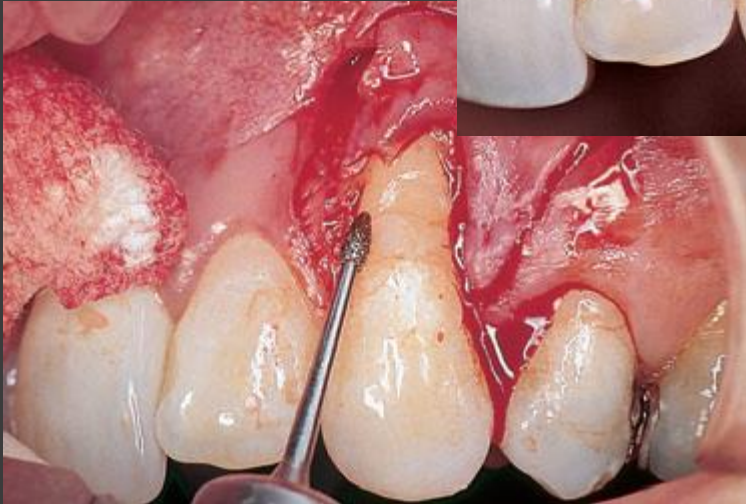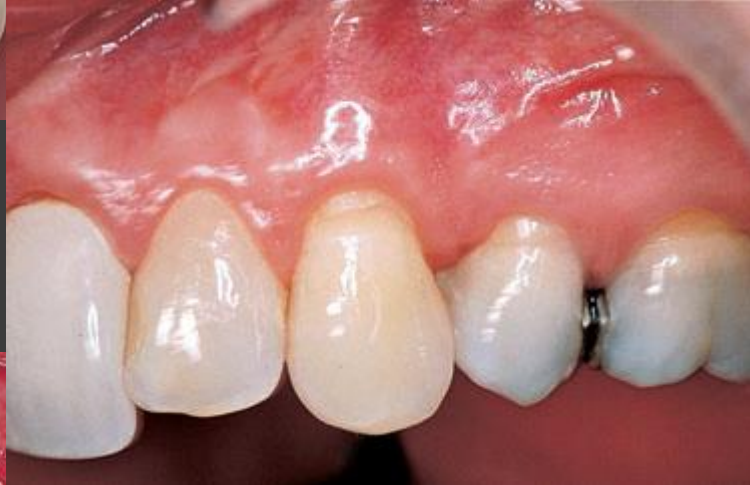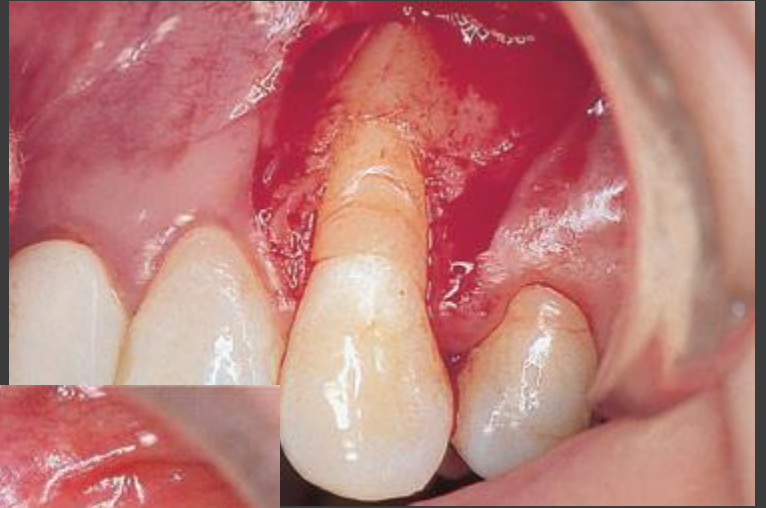
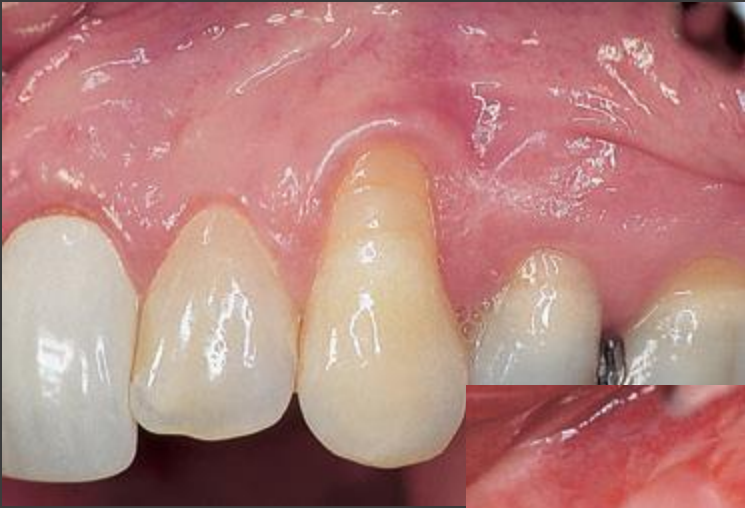# Coronally Advanced Flaps

- Used for root coverage of a single tooth as well as multiple teeth.
- Shallow recession defects and minimal probing pocket depth labially → ***semilunar coronally repositioned flap*** (Harlan 1907; Tarnow 1986).
- Isolated deep gingival recession lower incisor, or the mesial root of the first maxillary molar → ***laterally moved and coronally advanced flap***  
(*laterally moved and coronally advanced flap*)

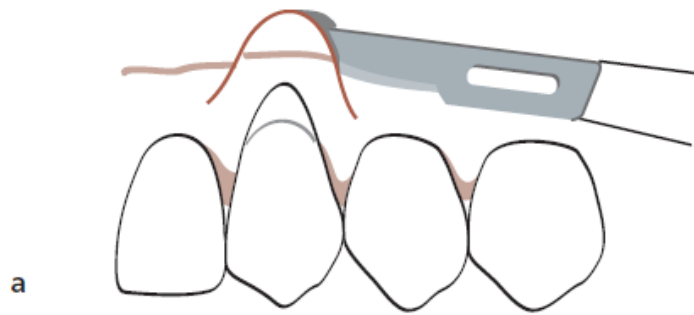
# The Technique For A *Coronally Advanced Flap* Procedure



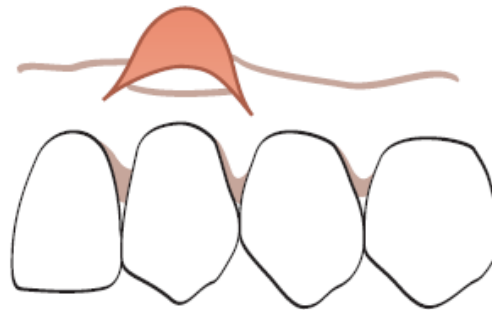
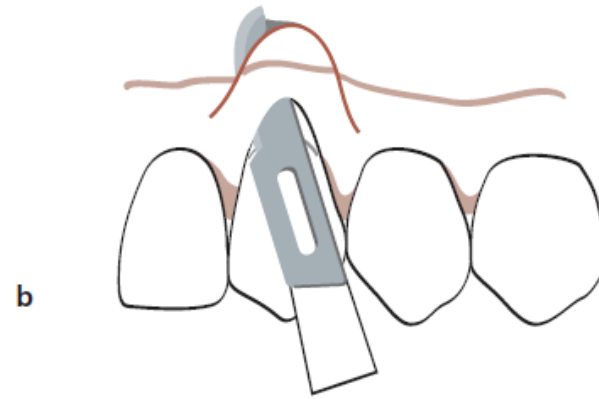




# Semilunar Coronally Repositioned Flap Procedure



**3 mm greater than  
the depth of the recession**



# Free Soft Tissue Graft Procedures

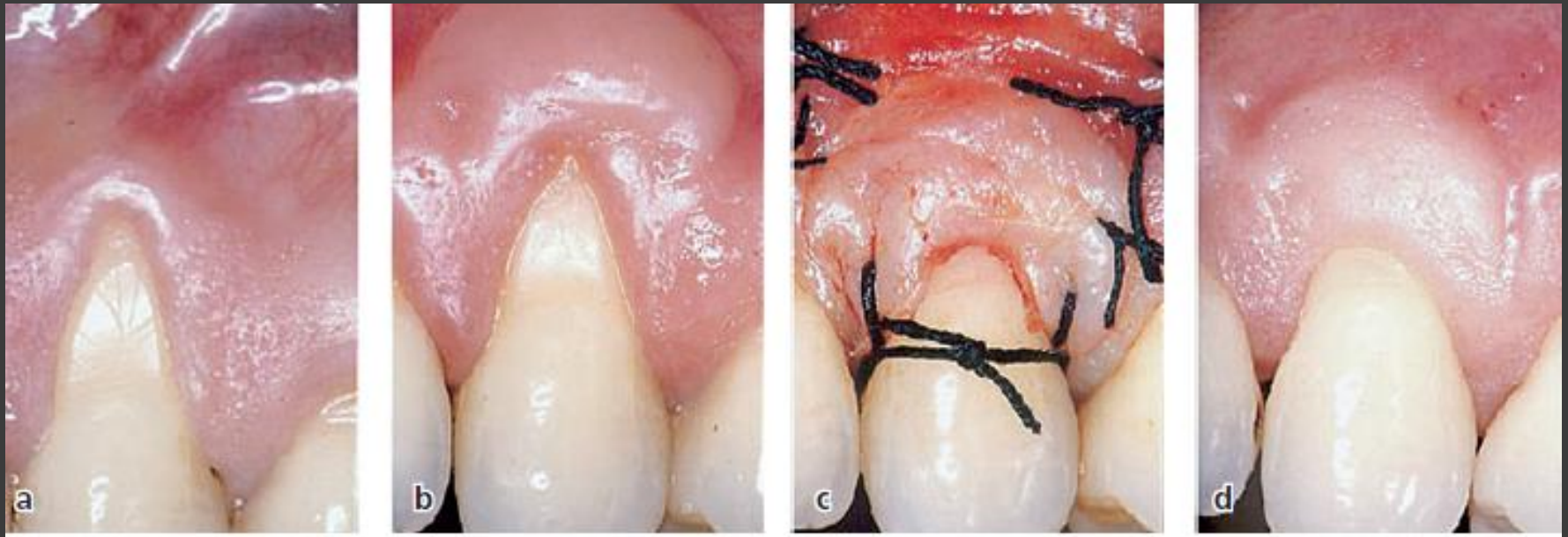
- Usually selected when there is **no acceptable donor tissue present** in the area adjacent to the recession defect or when a thicker marginal tissue is desirable.
- **The graft used may either be :**
  - (1) *epithelialized graft*
  - (2) *subepithelial connective tissue graft*

# Epithelialized Soft Tissue Graft

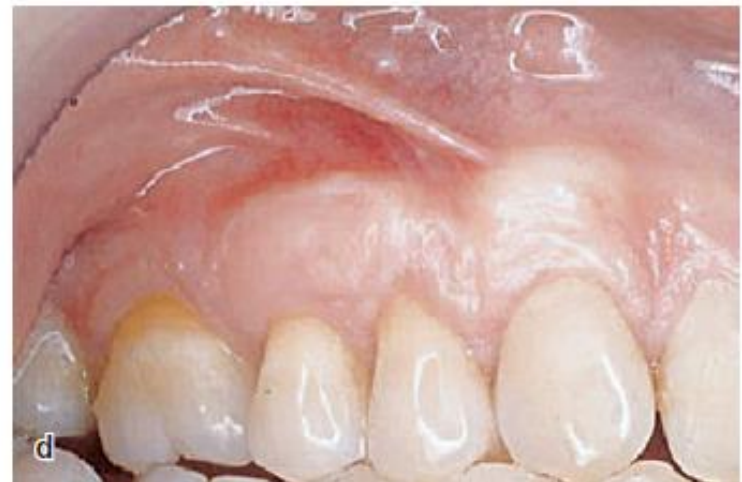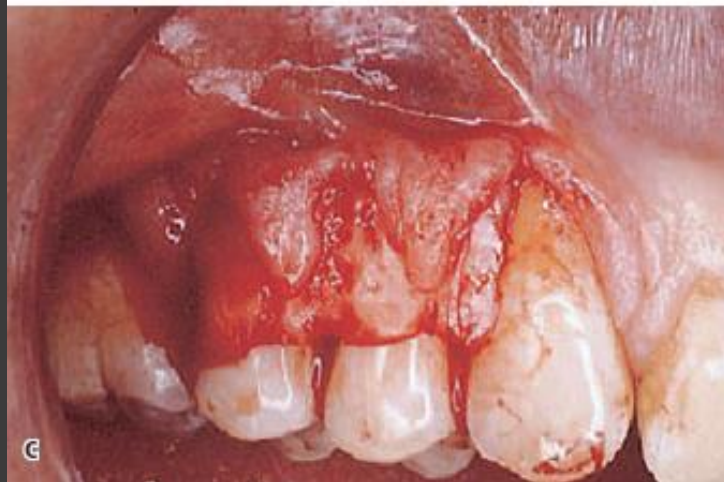
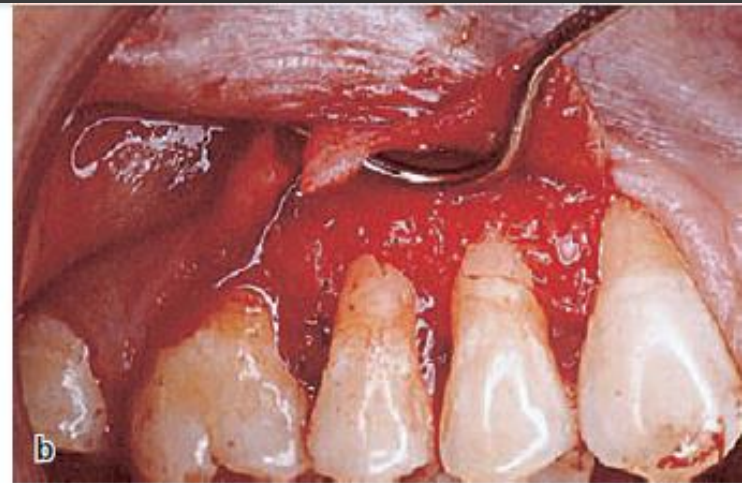
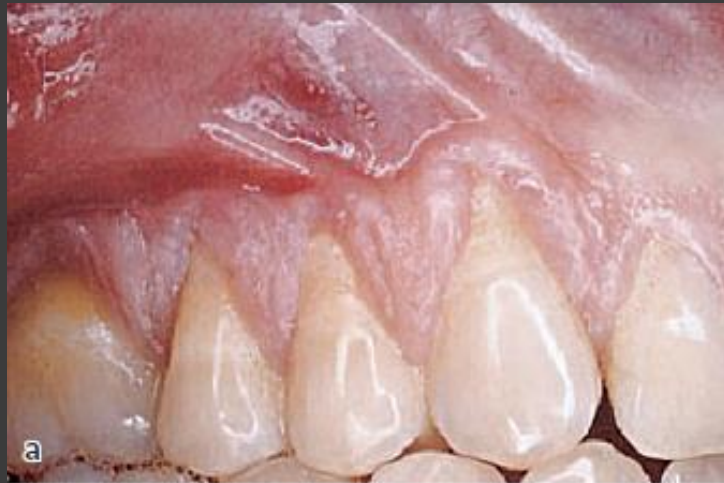Can be performed either as a

- **one step:** The graft is placed directly over the root surface (Sullivan & Atkins 1968; Miller 1982)
- **two-step:** Epithelialized free soft tissue graft is placed apical to the recession and following healing is positioned coronally over the denuded root (Bernimoulin 1975; Guinard & Caffesse 1978)

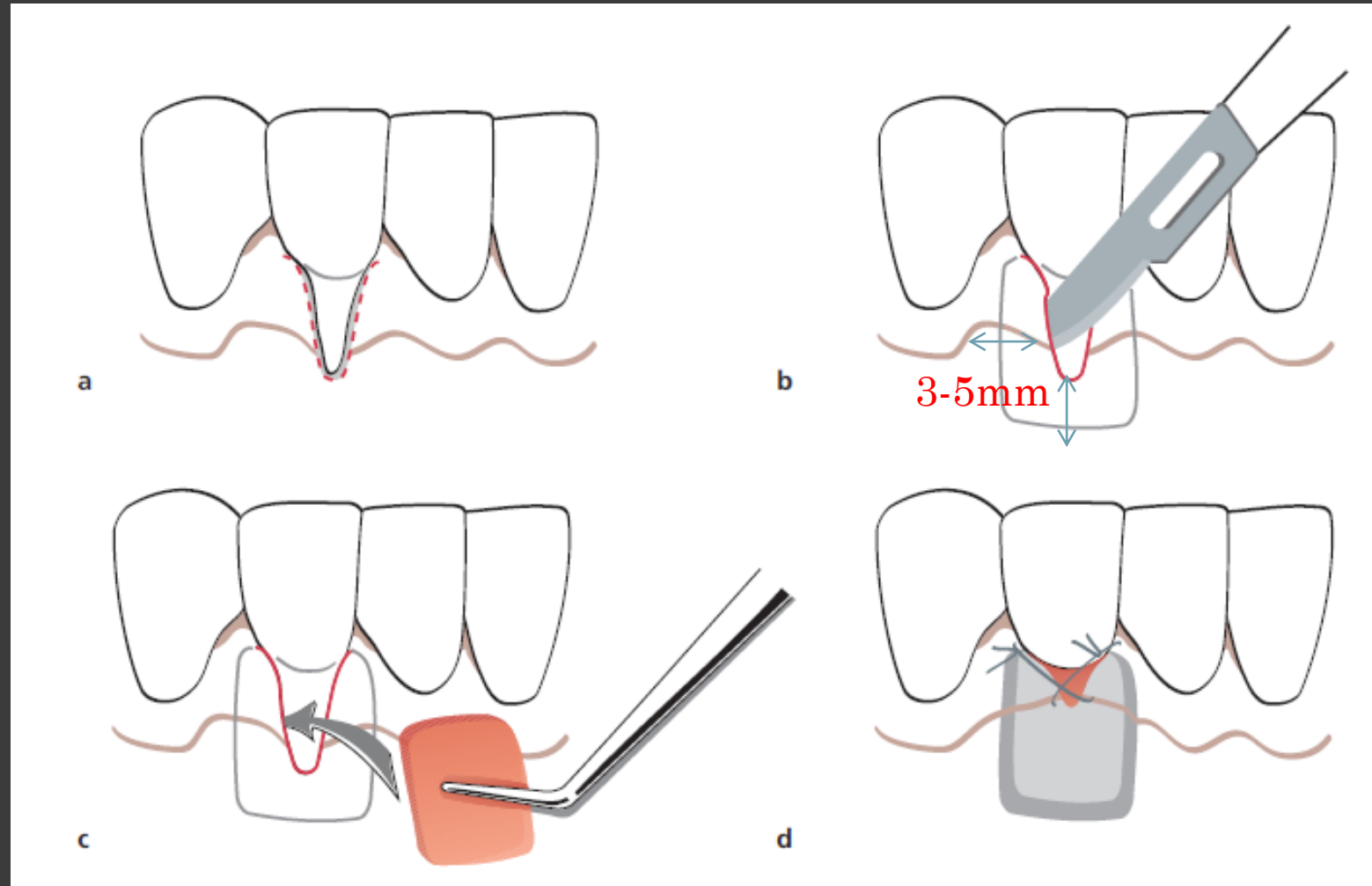
# Bernimoulin Procedure



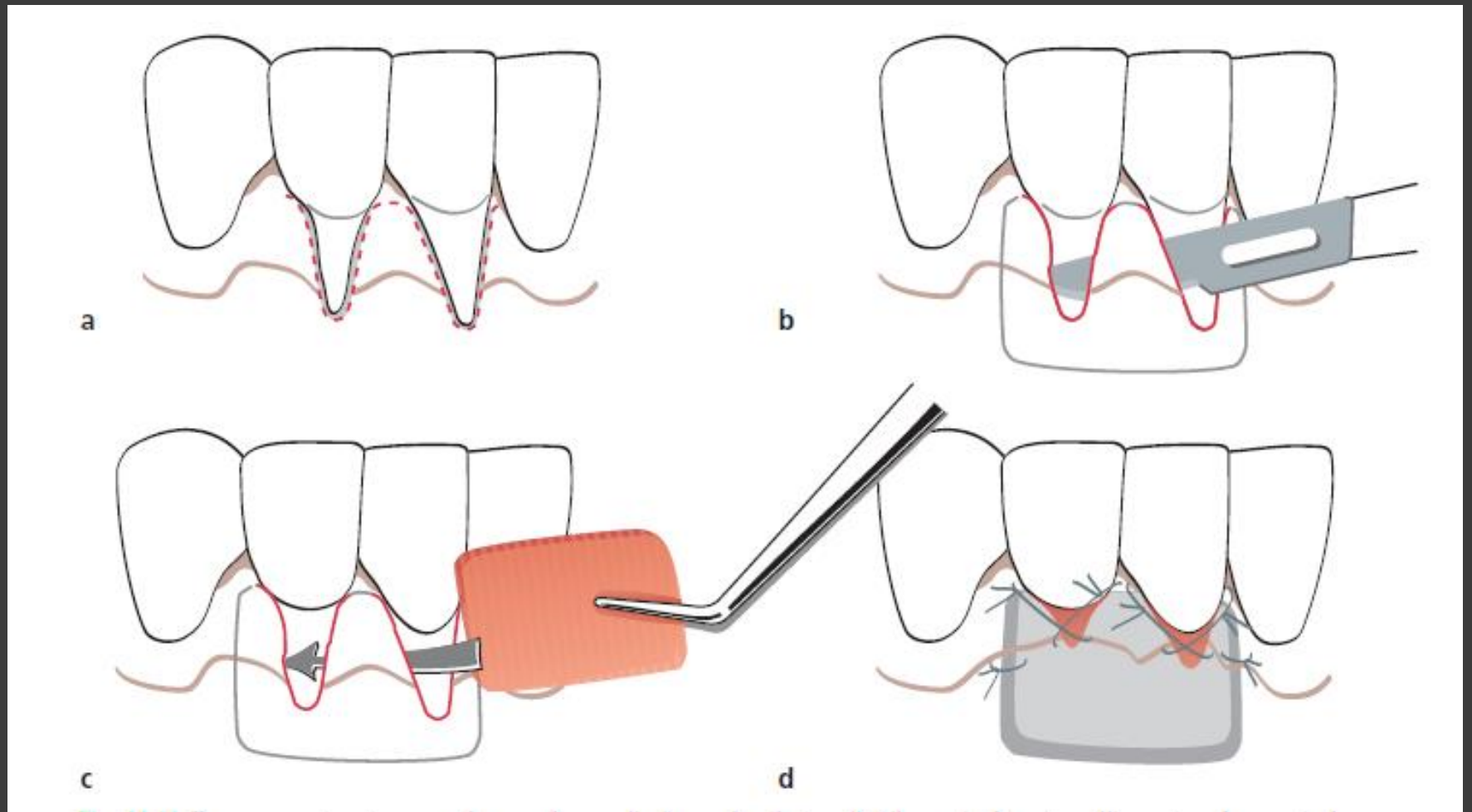
# Free Connective Tissue Graft Combined With A Coronally Advanced Flap Procedure



# Envelope Technique

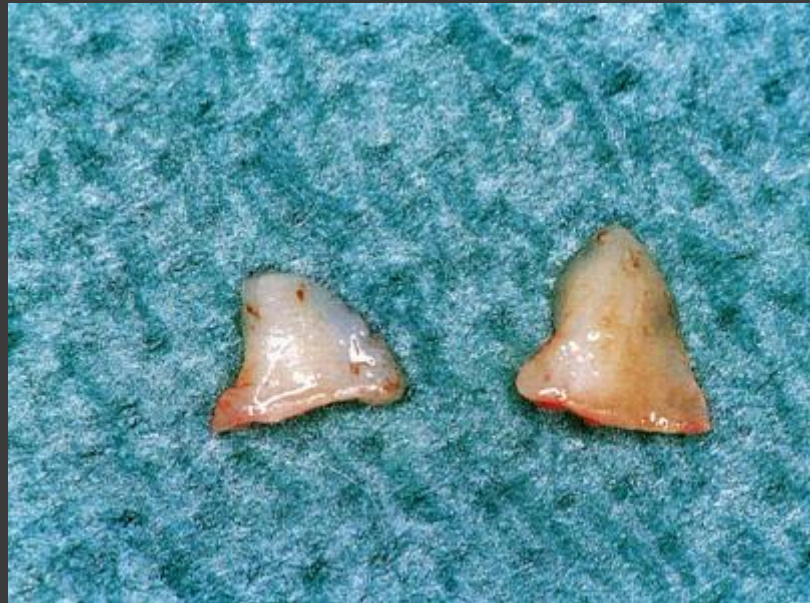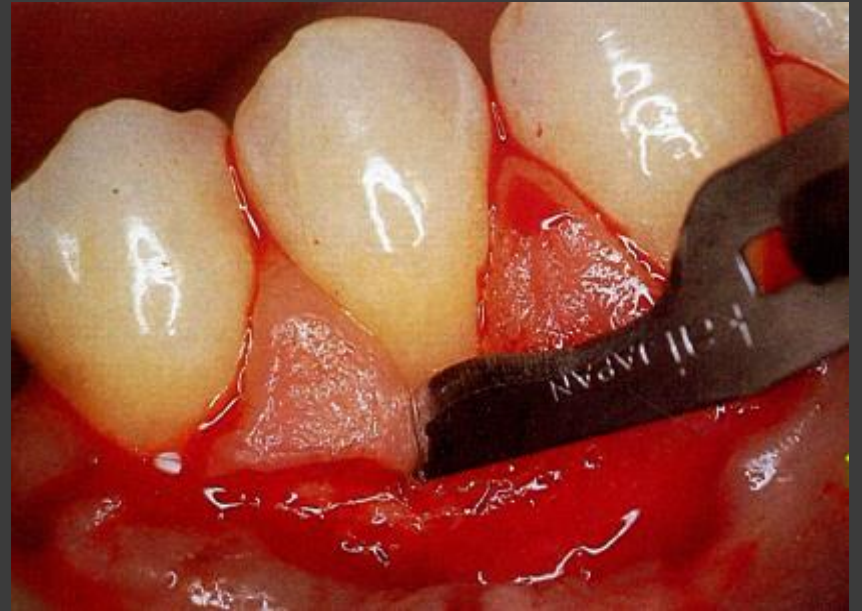
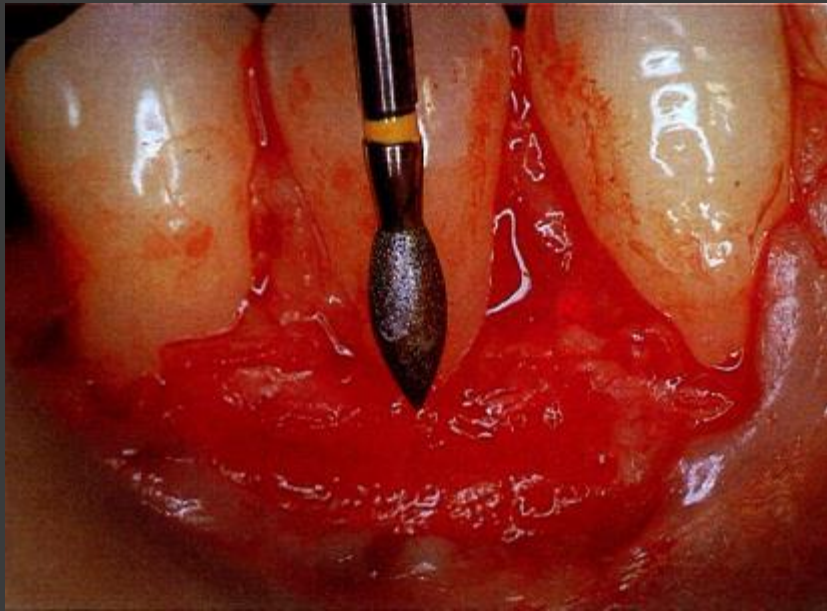


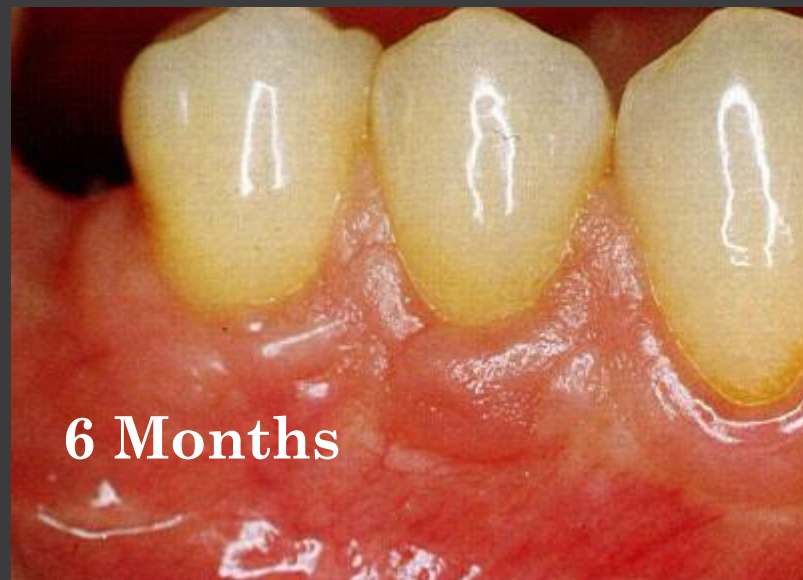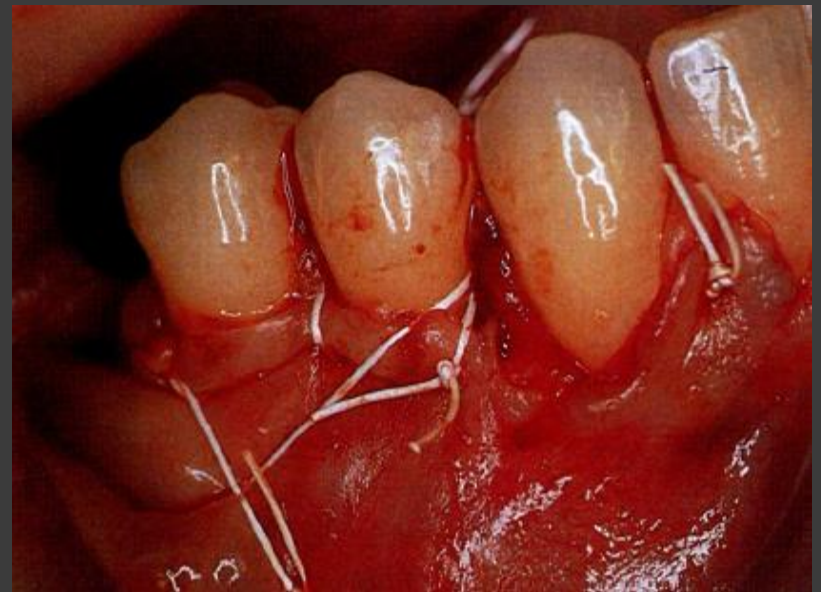
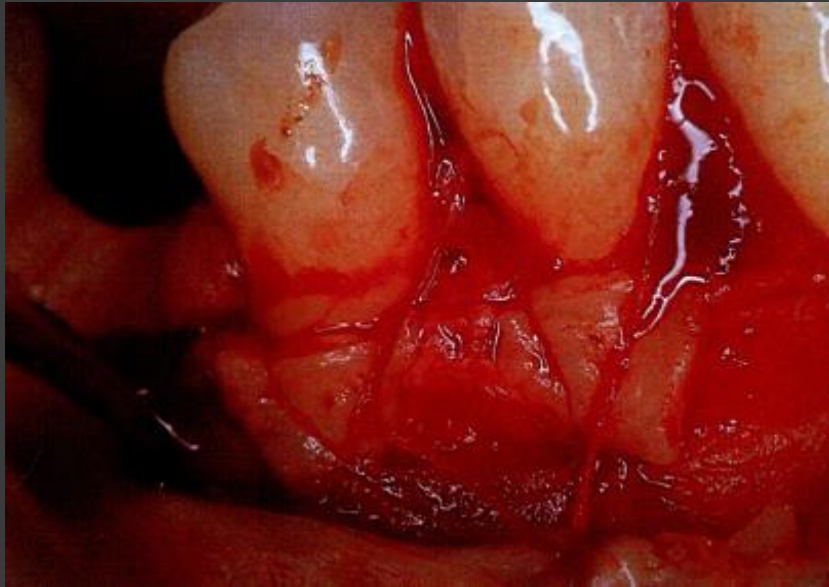
# Tunnel Technique





# The Free Rotated Papilla Autograft





# Periodontal Soft Tissue Root Coverage Procedures: A Systematic Review From the AAP Regeneration Workshop

Leandro Chambrone\* and Dimitris N. Tatakis†

J Periodontol • February 2015 (Suppl.)

## Miller Class I and II GR.

All RC procedures can provide significant reduction in recession depth and CAL gain without alteration of PD for Miller Class I and II localized recession-type defects.

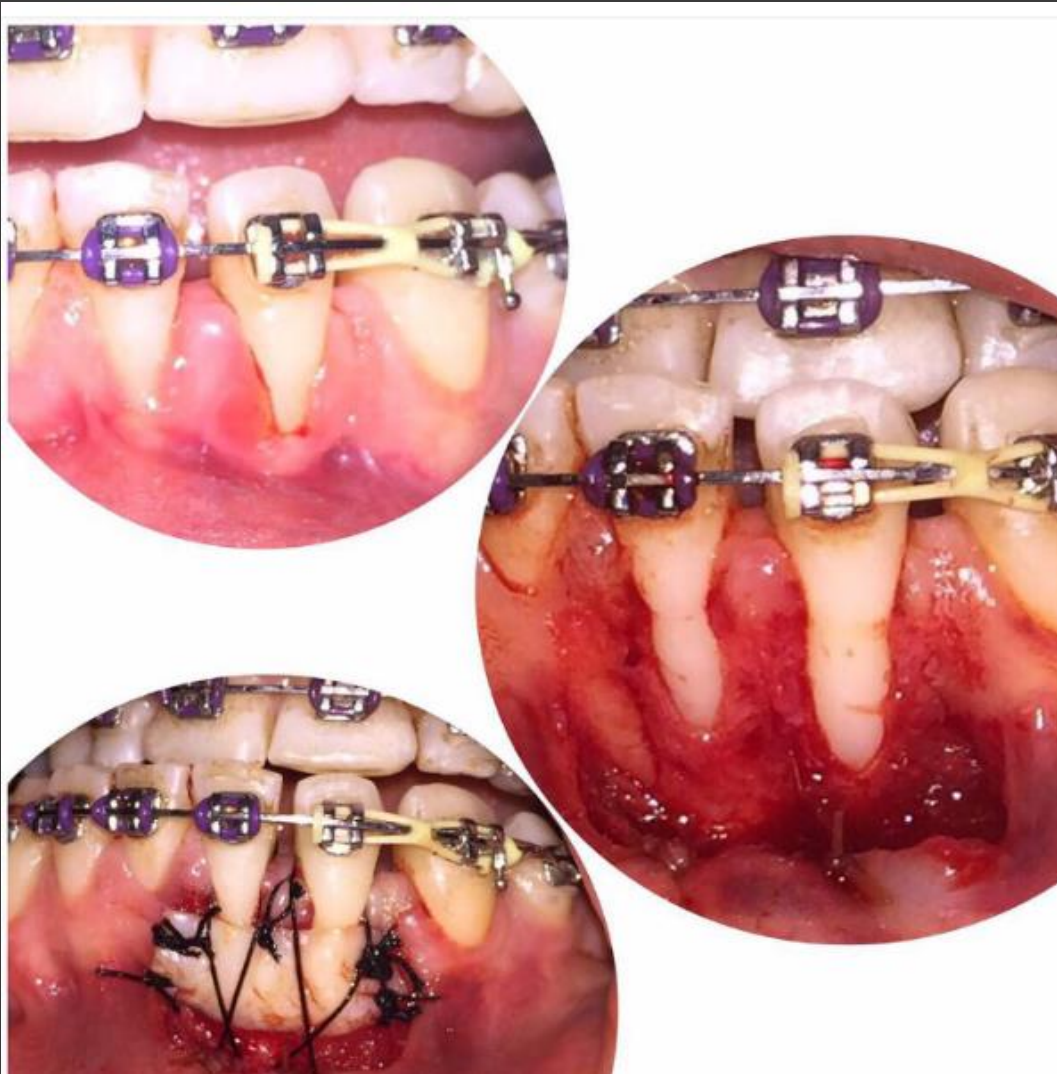SCTG-based procedures provided the best outcomes for clinical practice because of their superior percentages of CRC and the significant increase of KT.

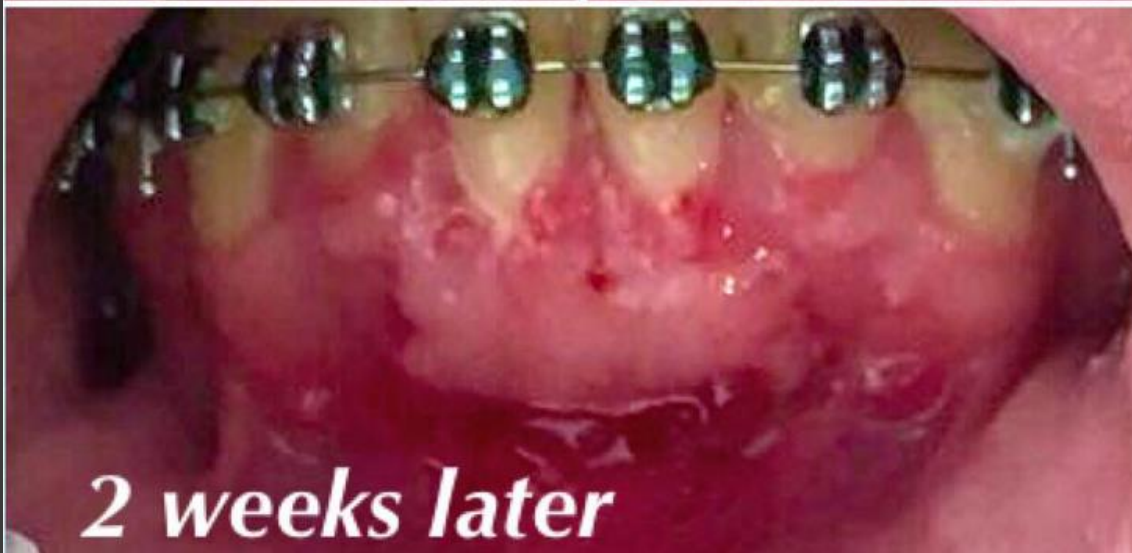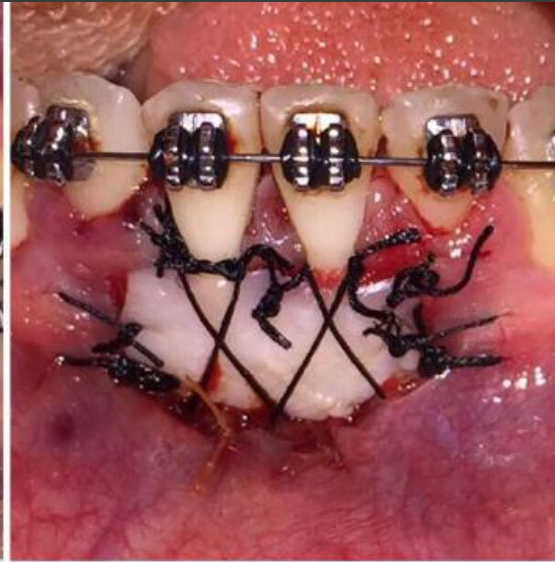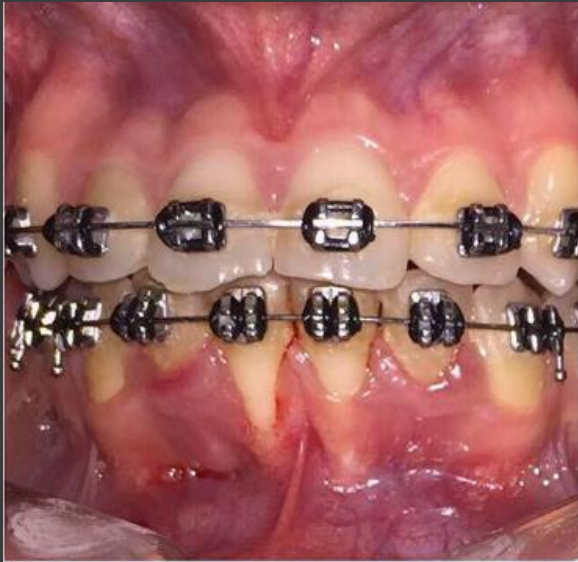## Miller Class III and IV GR.

Class III defects may significantly benefit from the use of RC procedures (in the short term) when SCTG-based procedures are used.

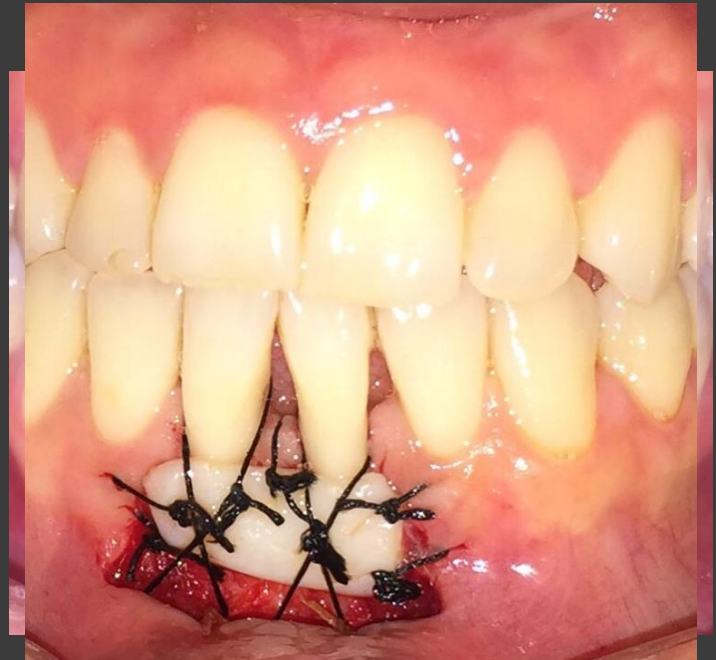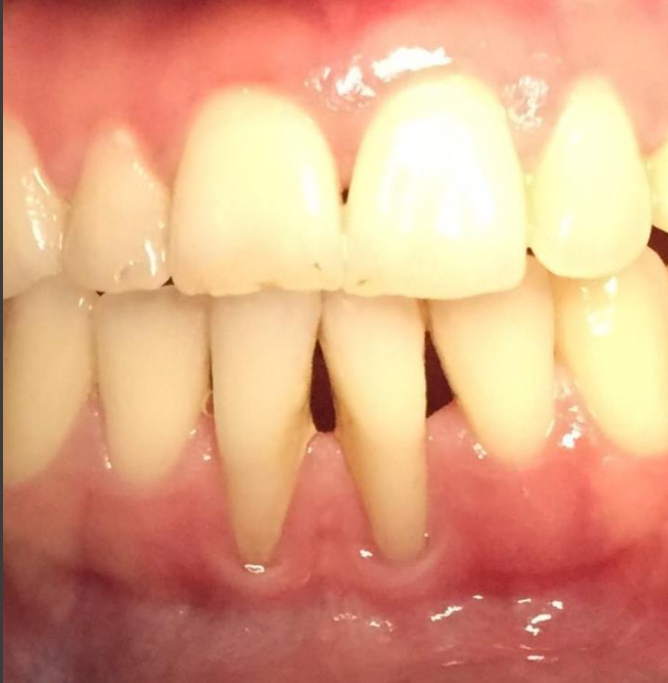Class IV recessions, the data from the limited number of case reports suggest that these defects may be improved after treatment, but the amount of RC cannot be anticipated, and restorative procedures may be necessary to reach the final expected esthetic outcomes.

It was clearly demonstrated that smoking may significantly decrease the effect of therapy, especially when SCTG-based procedures had been used

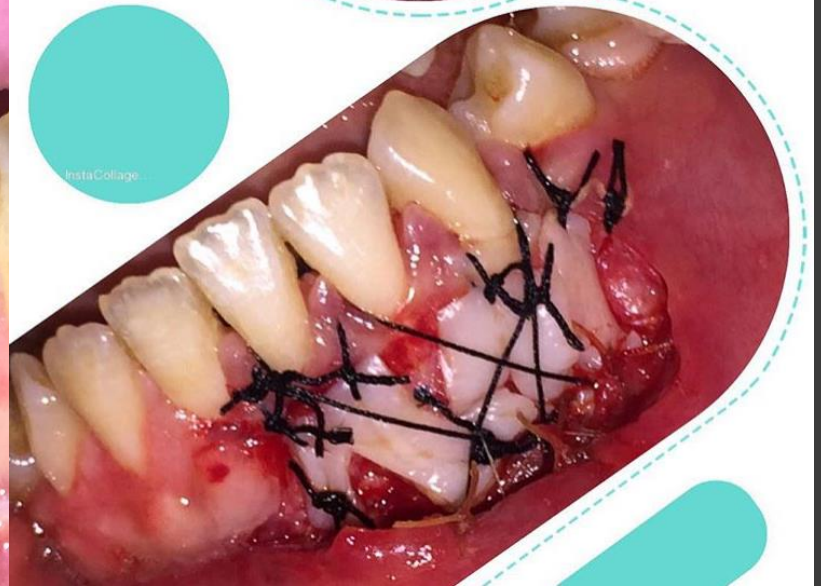
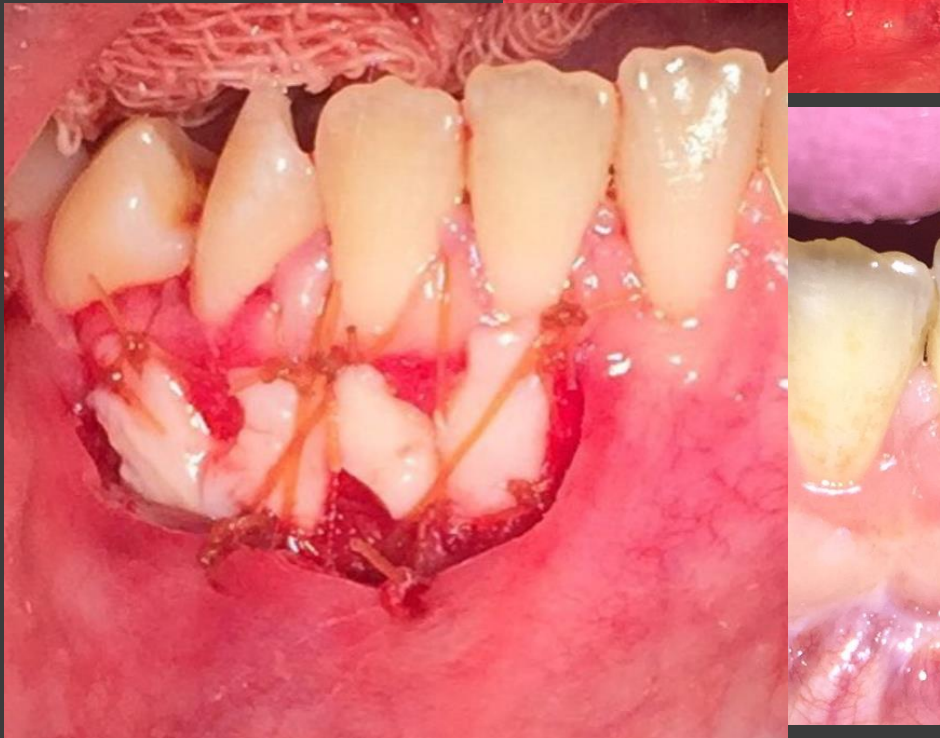
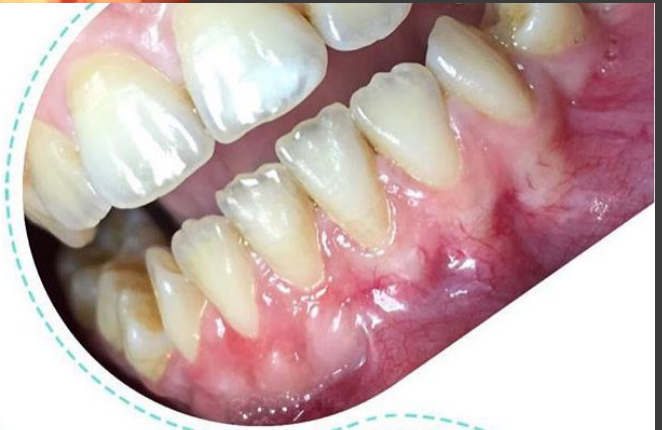
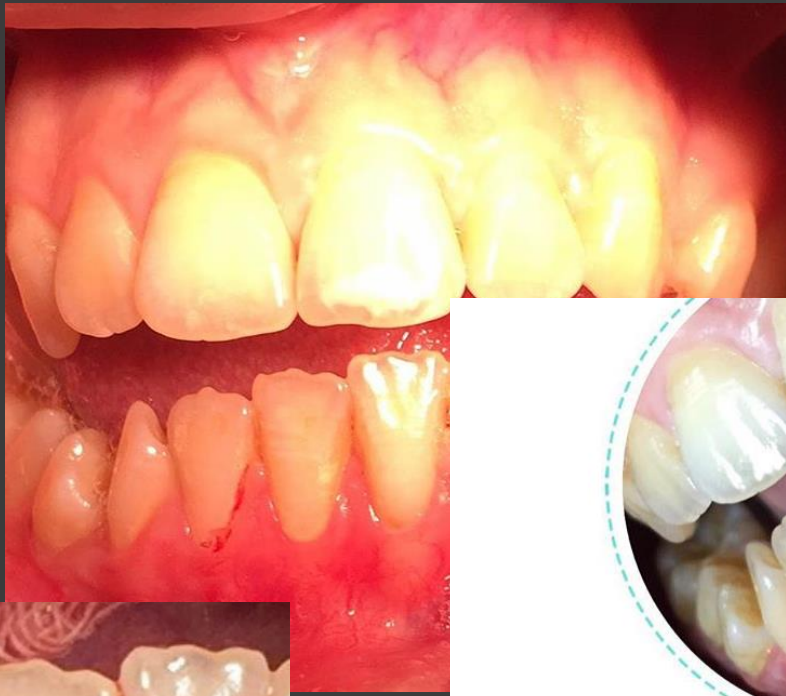


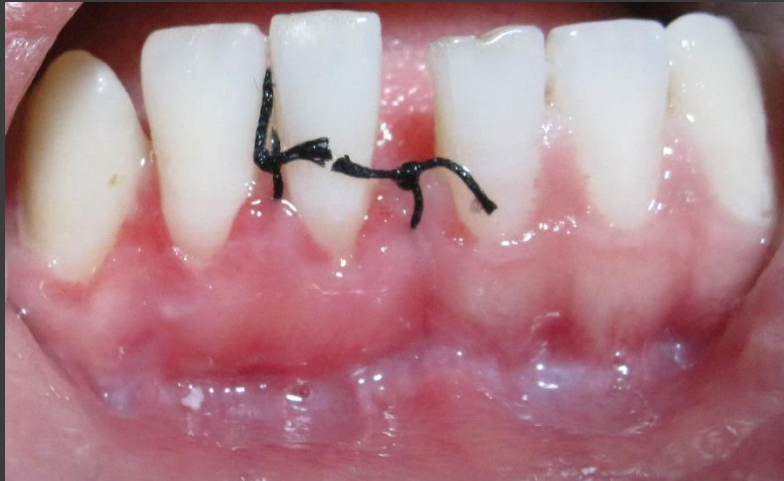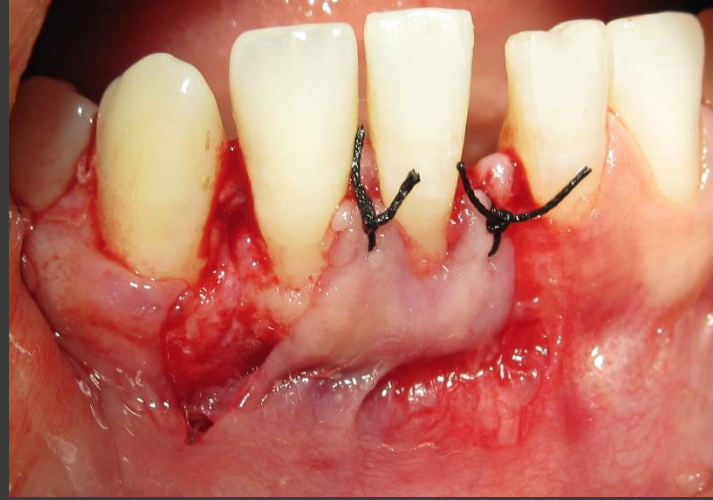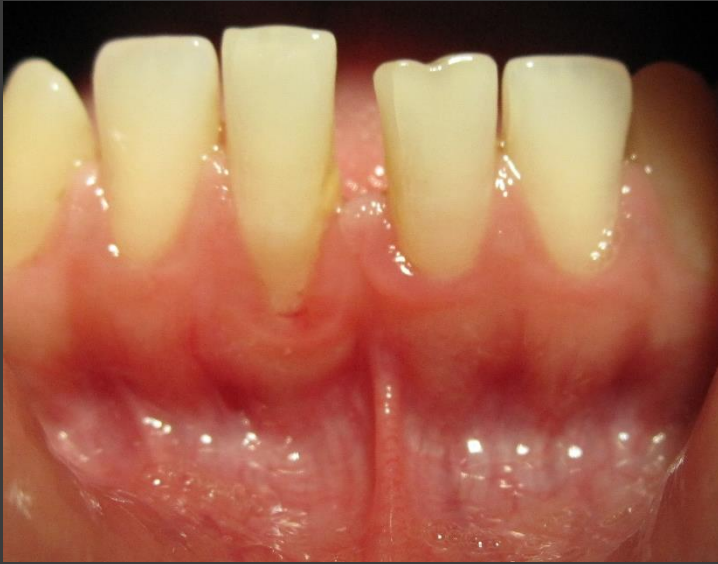*2 weeks later*











**THE END**