

# CONE BEAM COMPUTED TOMOGRAPHY IN ENDODONTICS

Dr. Reza Hatam

Assistant Prof. Dental school, Kermanshah Medical Sci.

*“Radiographic interpretation is central to diagnostic process.”*

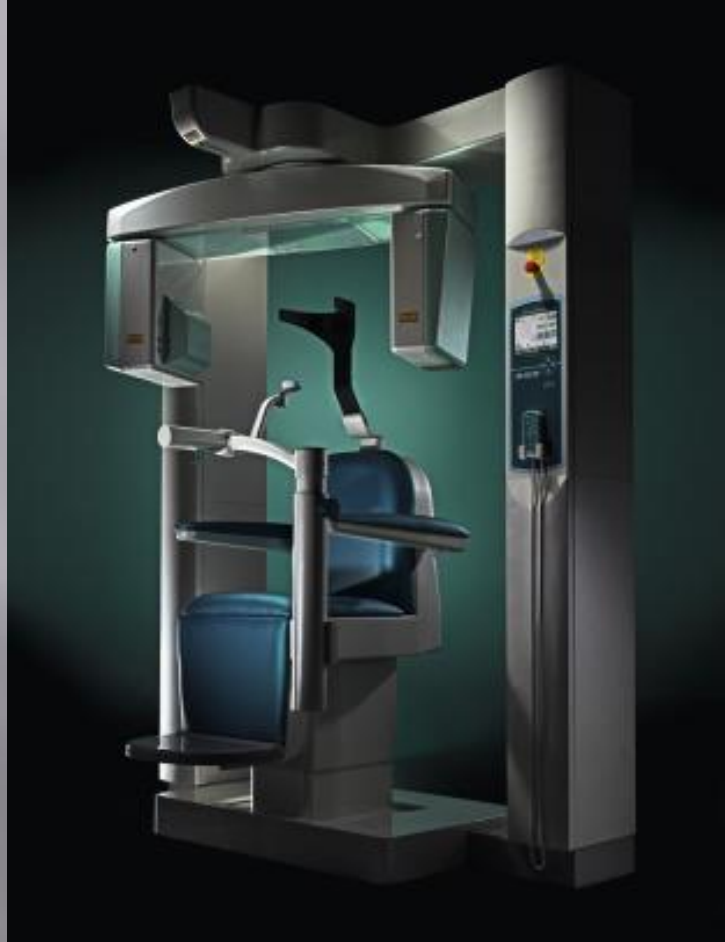
- ▣ Conventional intraoral
- ▣ Digital imaging modalities:

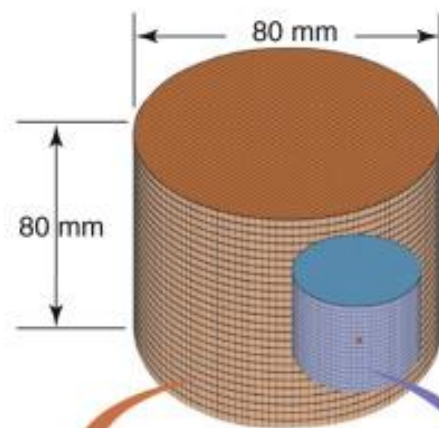
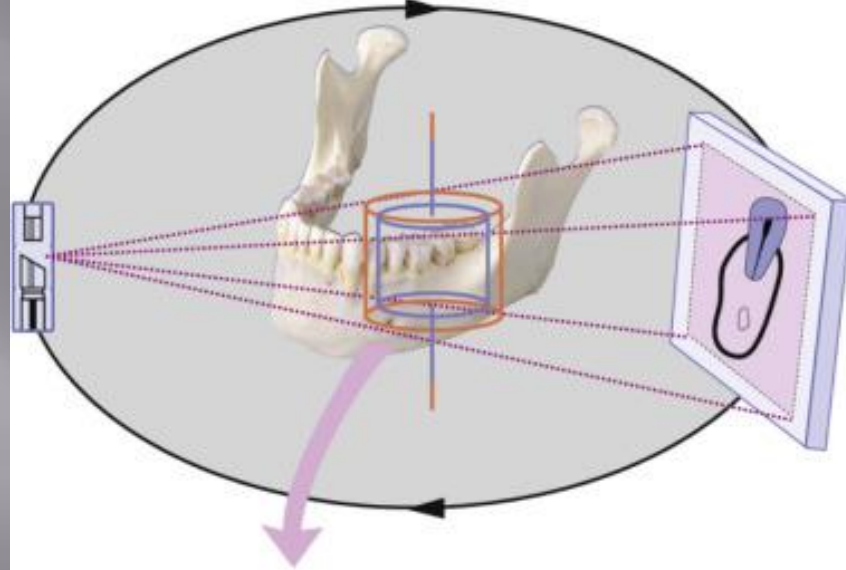
CCD

CMOS

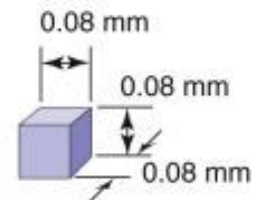
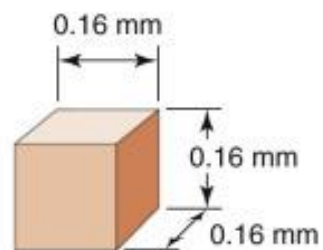
PSP

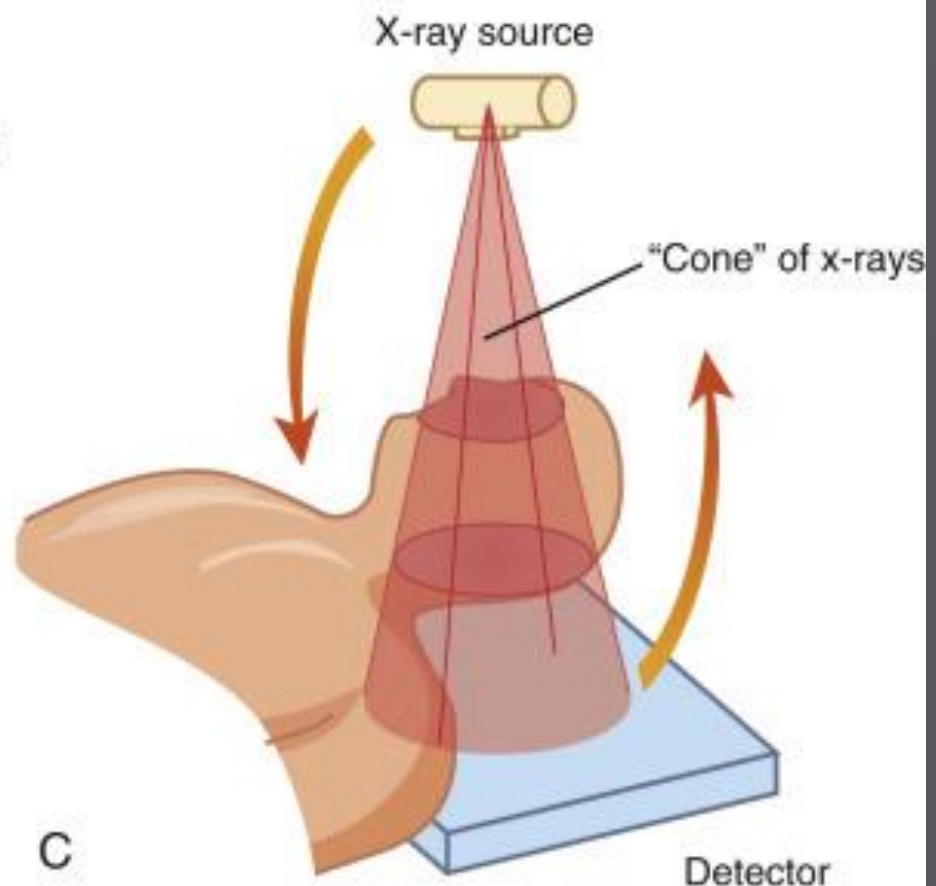
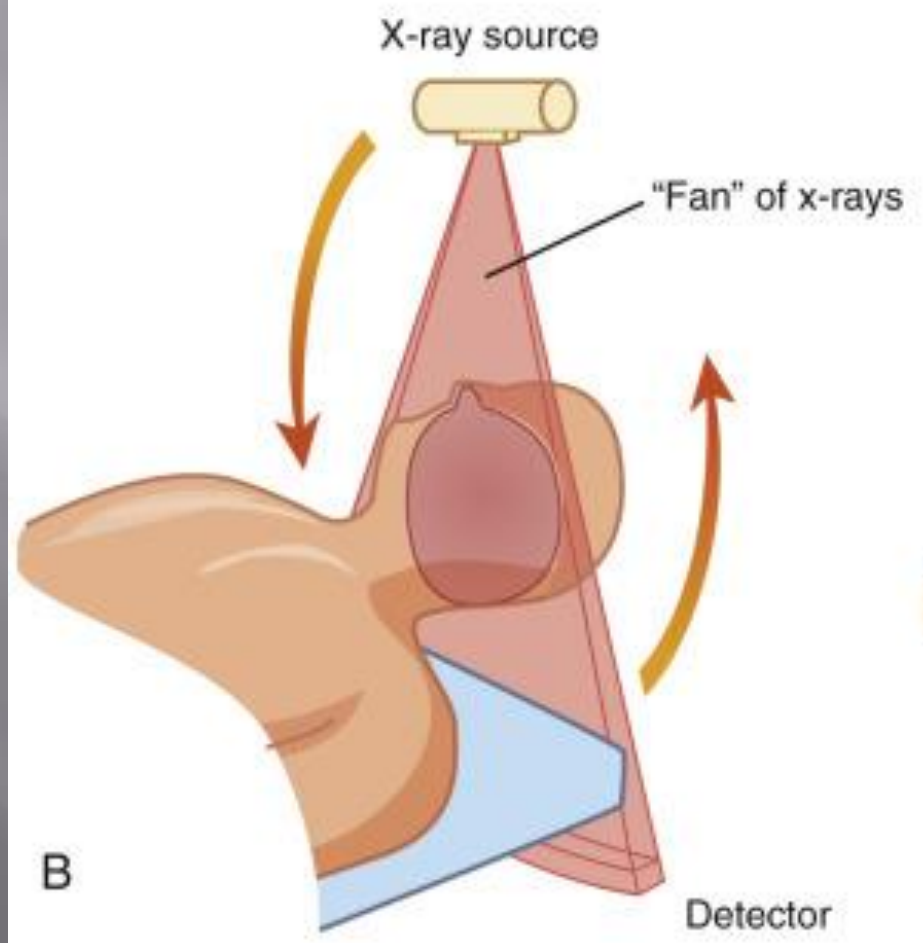
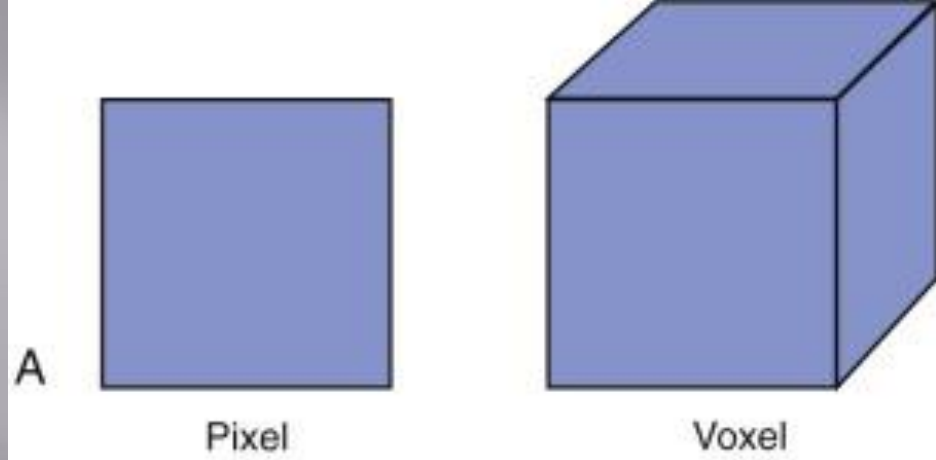
**CBCT**



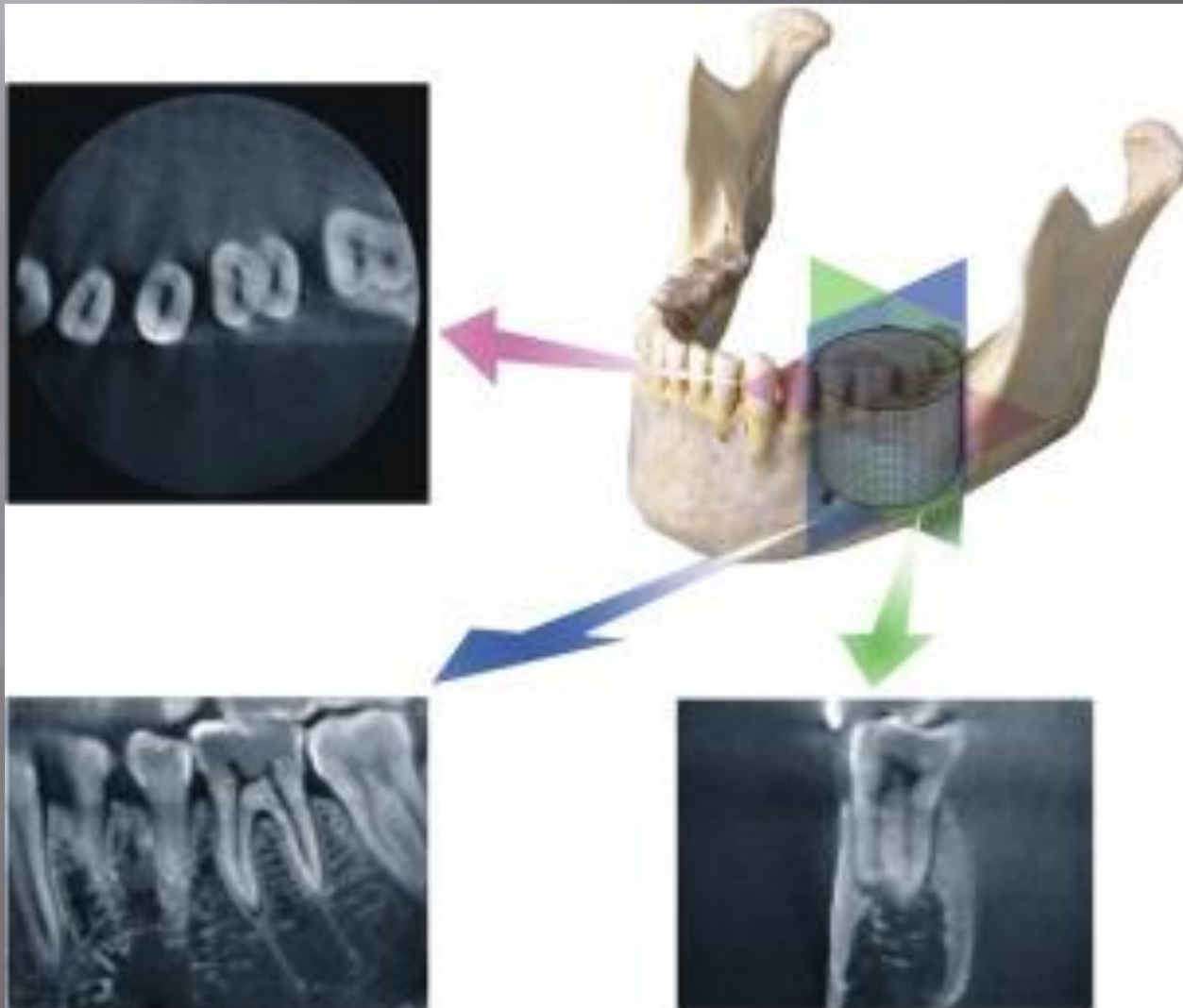


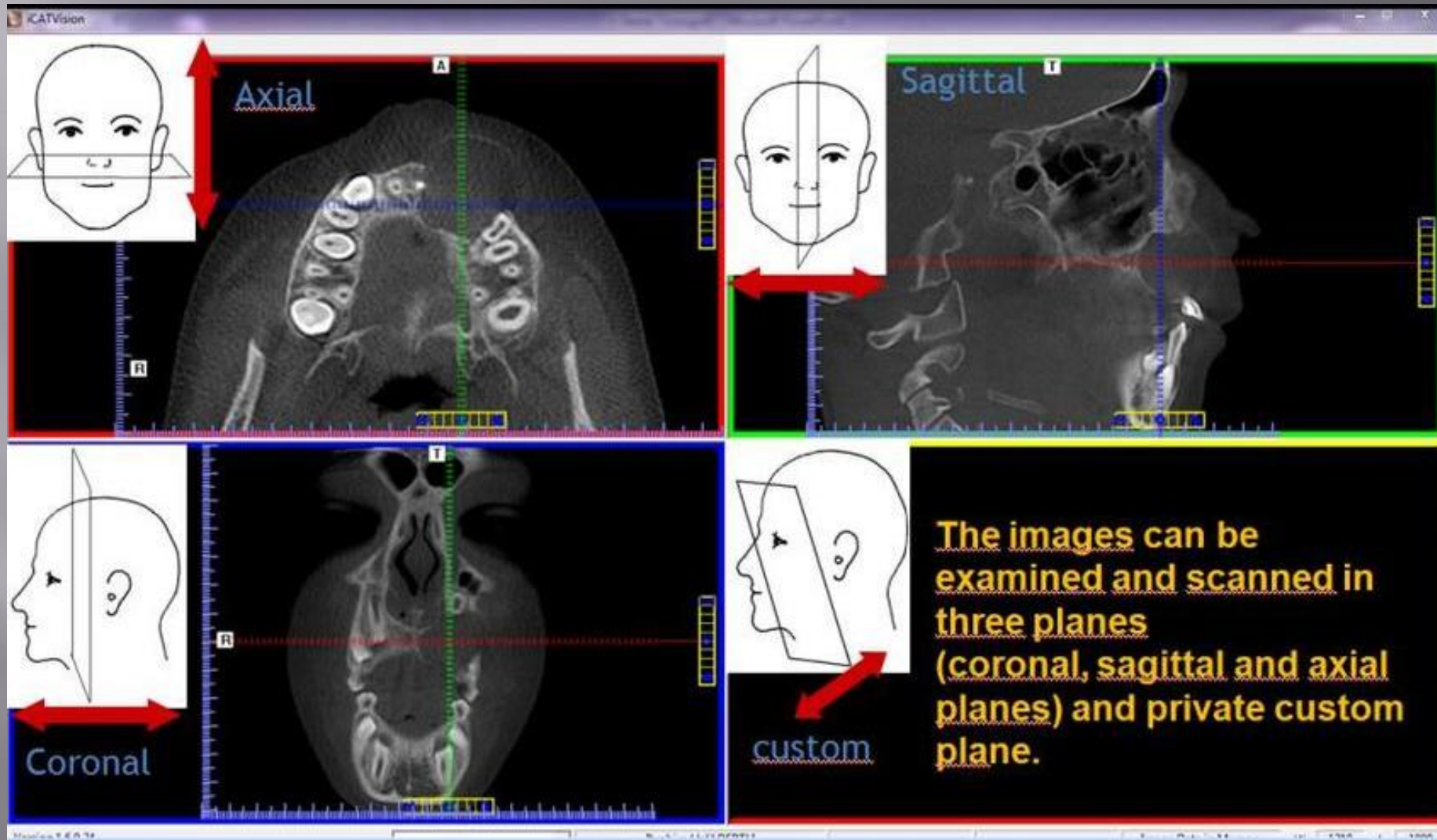
Voxel size





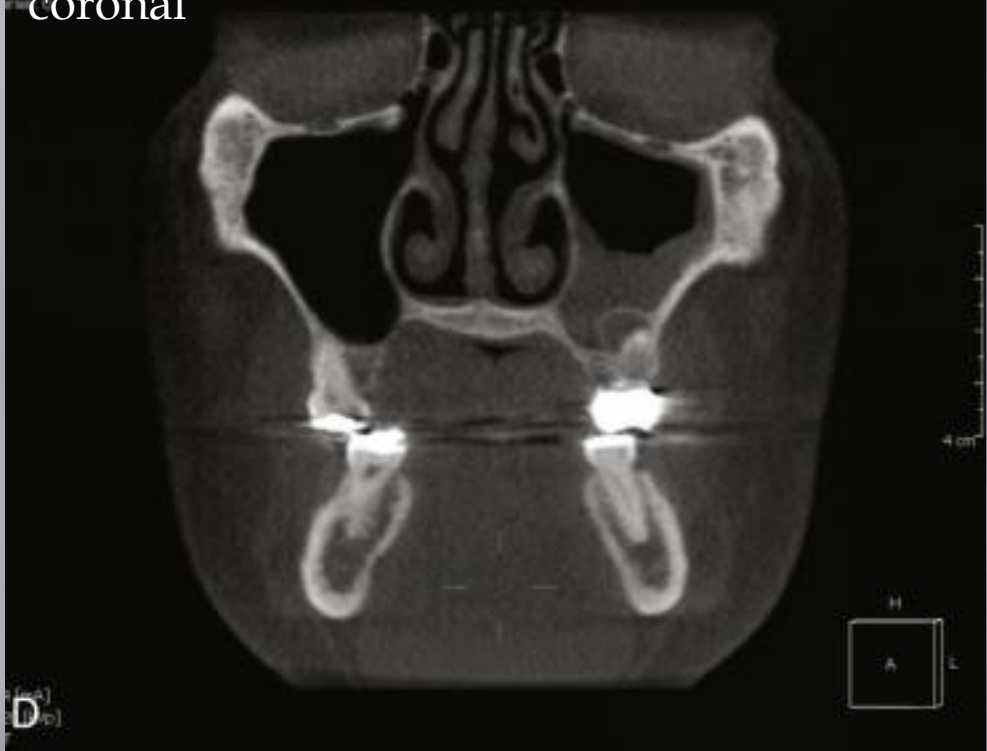# CBCT Cuts (views)





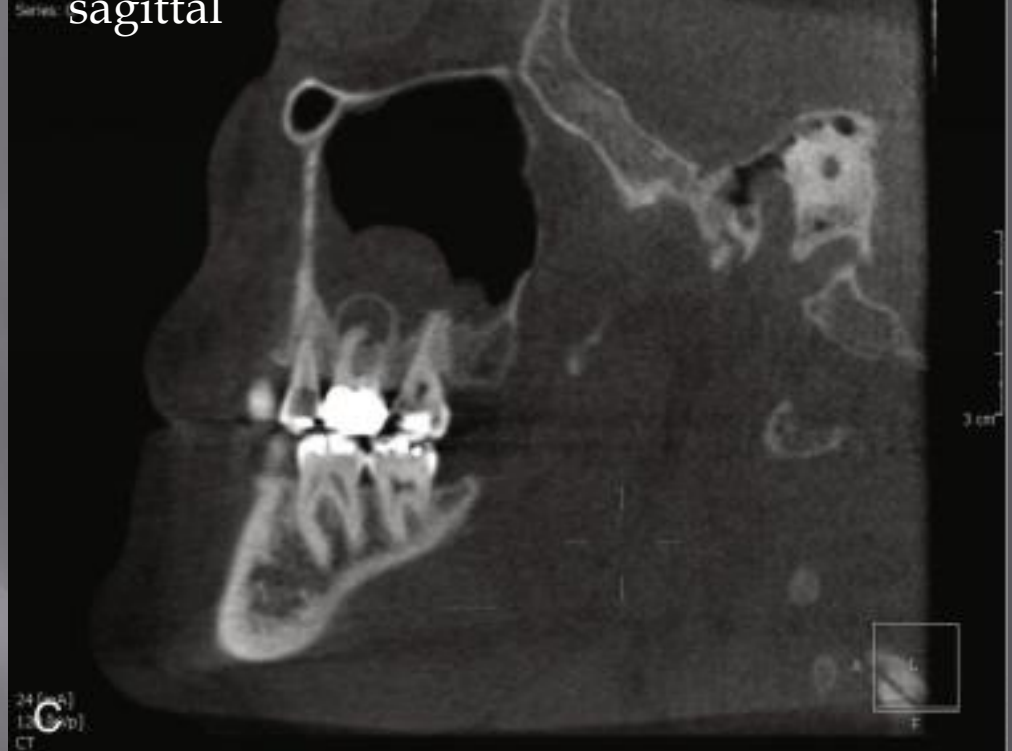ID: 903  
Paul Thompson  
20090306

coronal

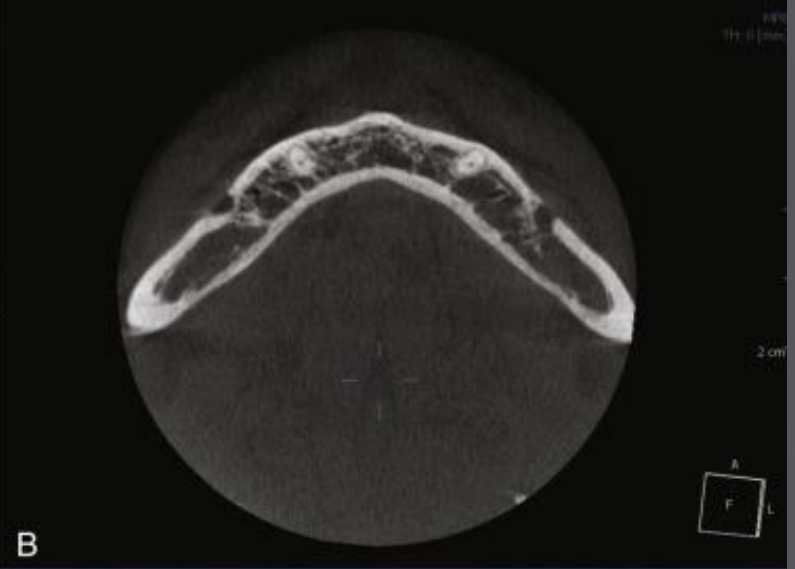
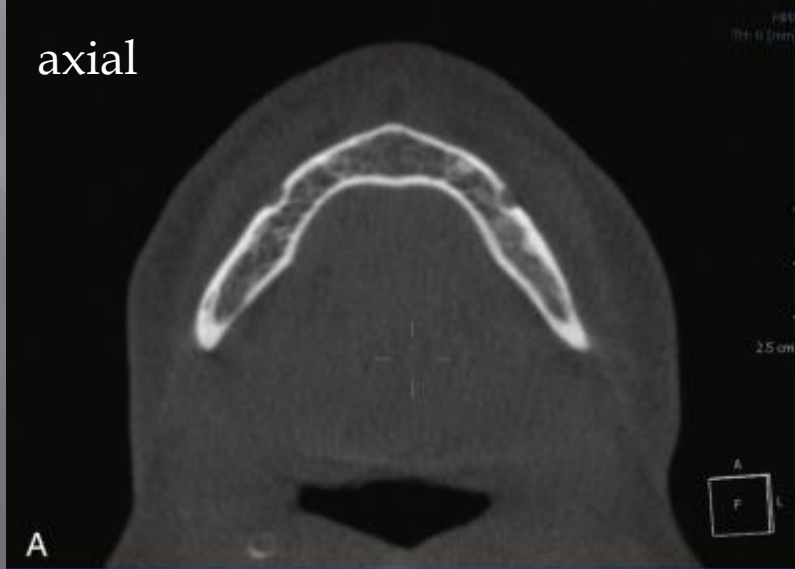


ID: 903  
Paul Thompson  
Series: 20090306

sagittal



axial

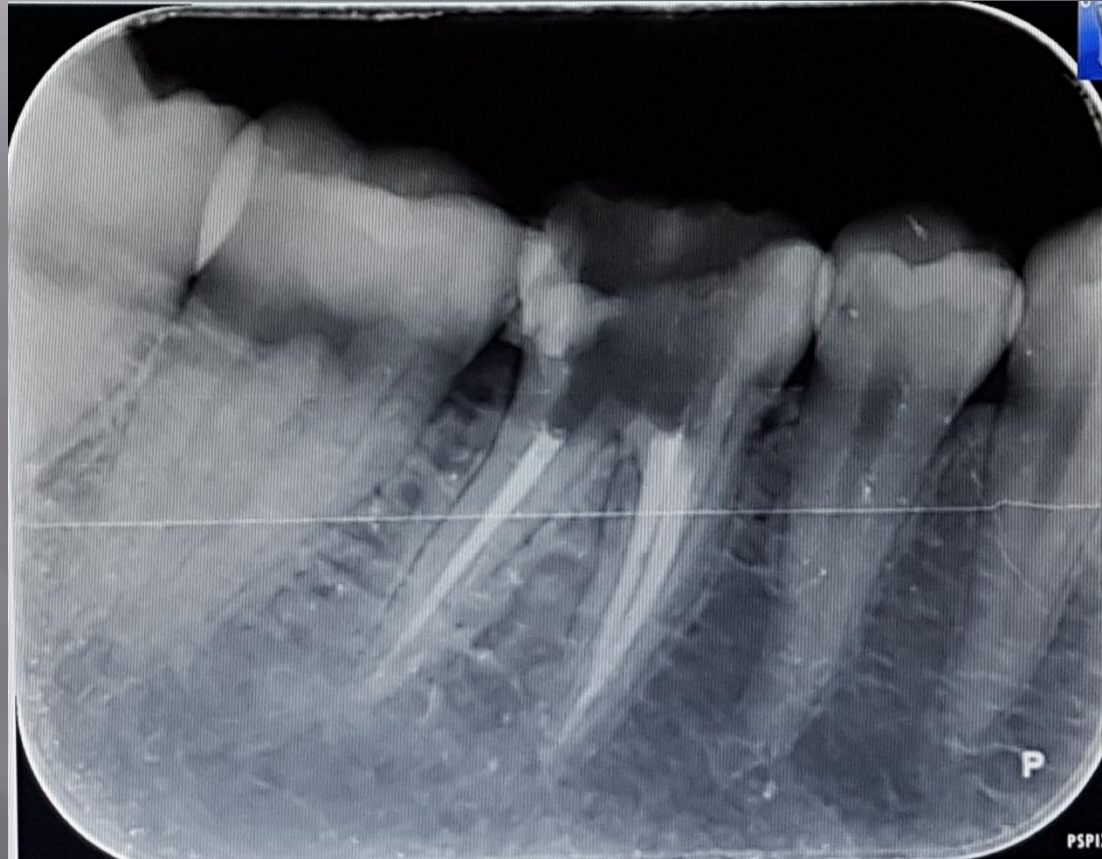




# Field of View

- ▣ Diagnostic task
- ▣ Type of patient
- ▣ Spatial resolution required

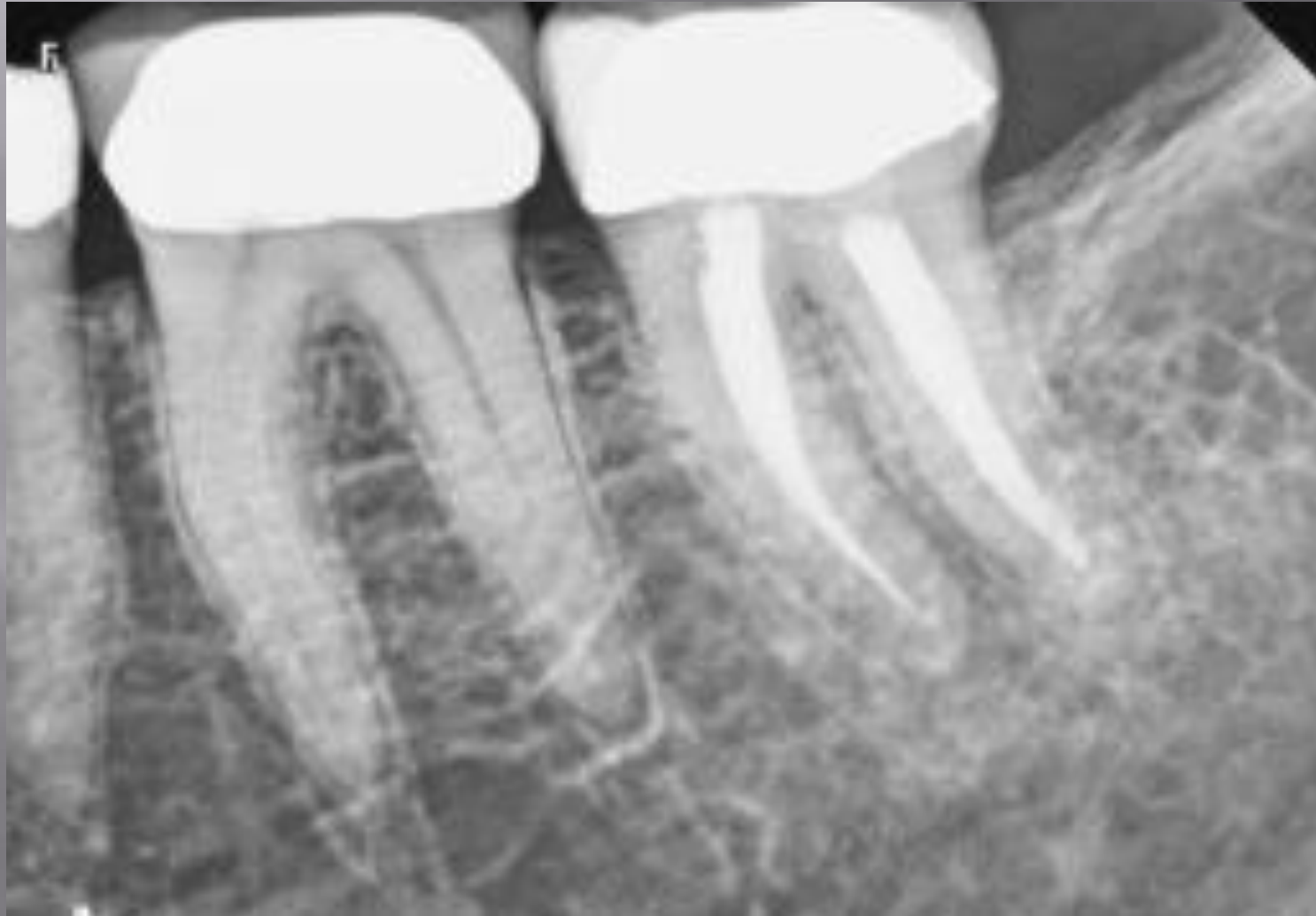# Determination of an extra root

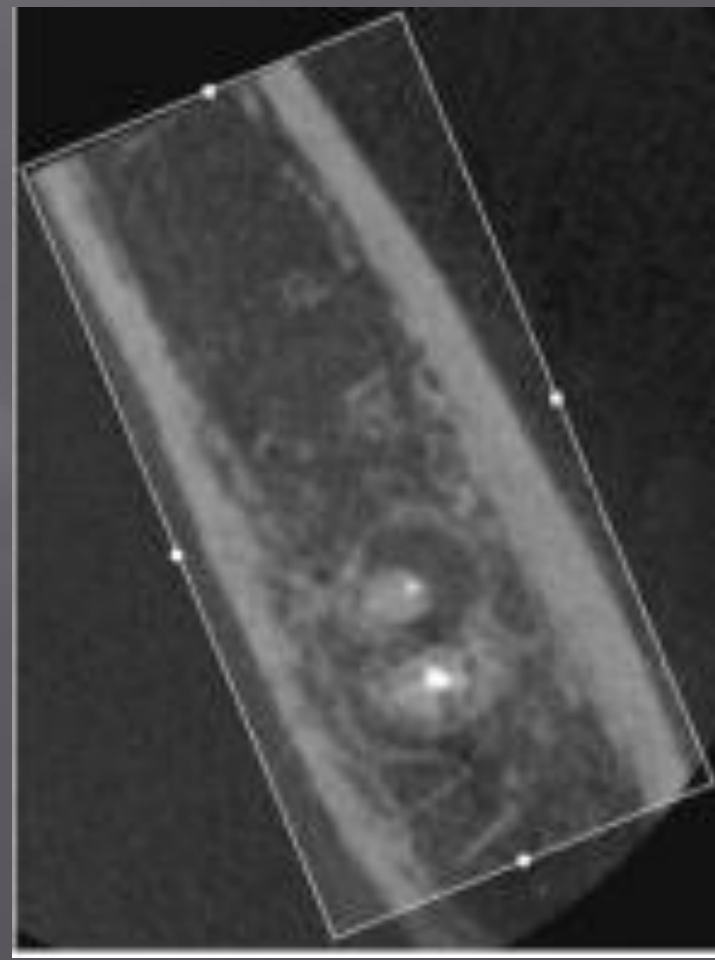
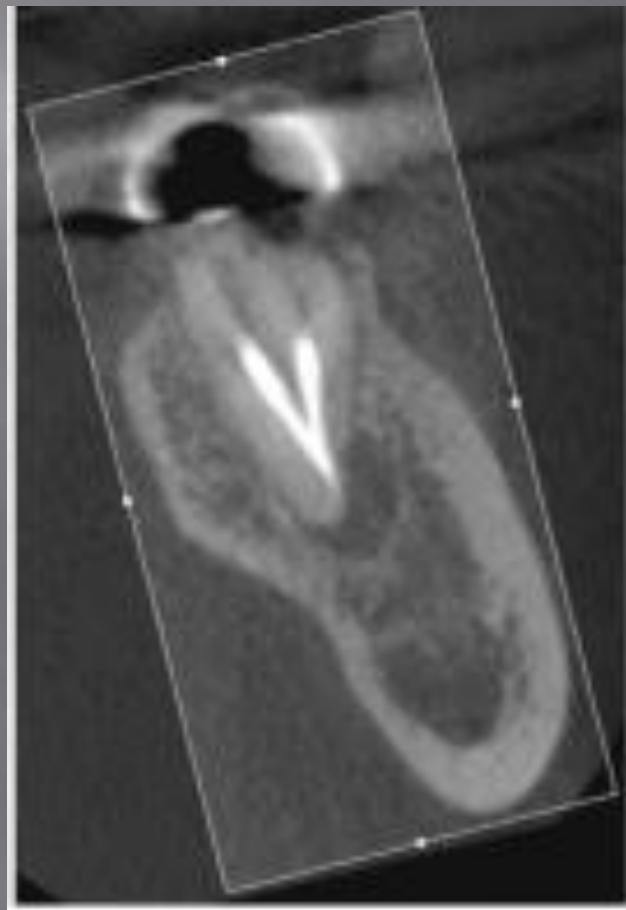
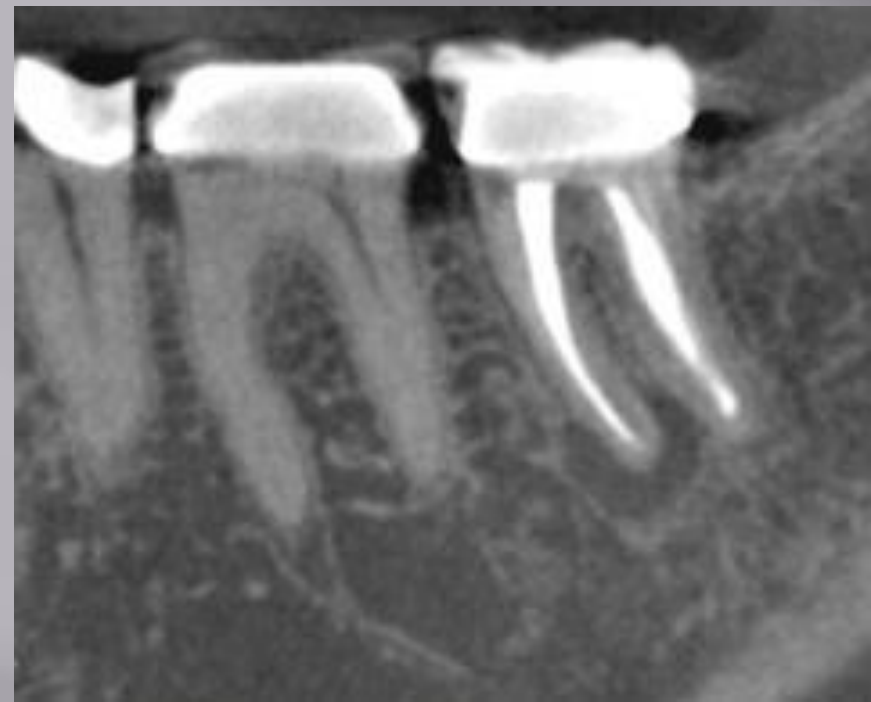


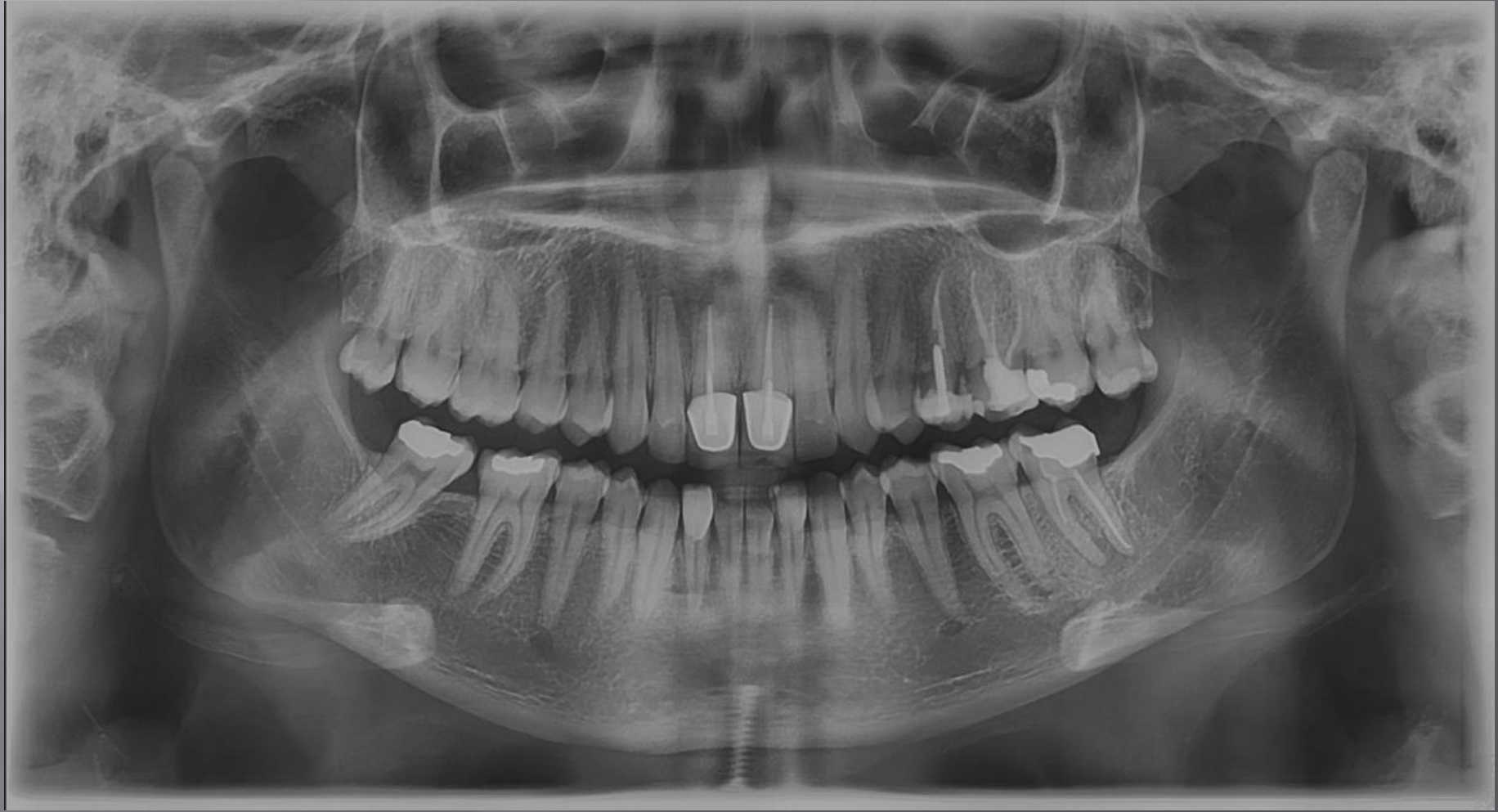# IMAGING TASKS IMPROVED OR SIMPLIFIED BY CBCT

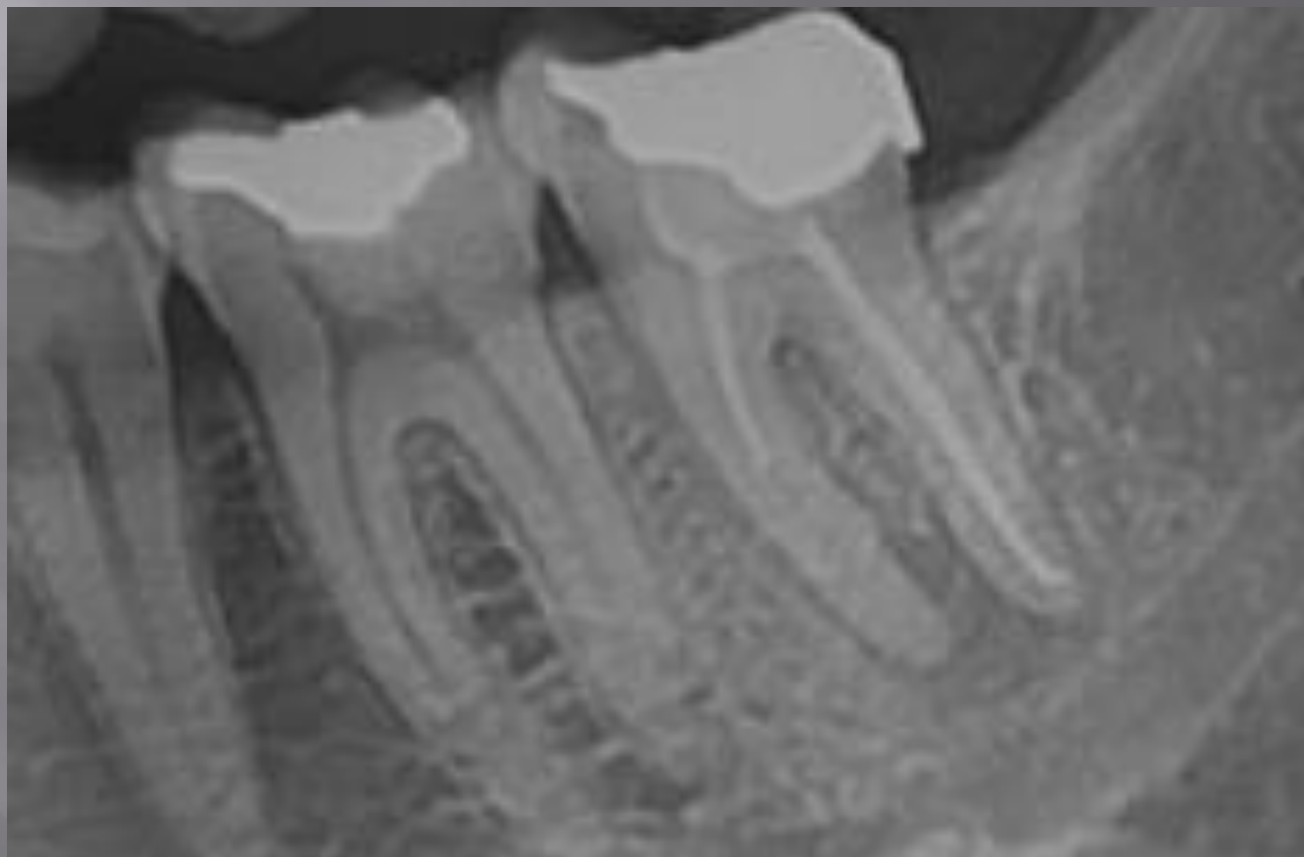
- ▣ Differential diagnosis
- ▣ Evaluation of anatomy and complexity
- ▣ Intraoperative or postoperative assessment of endodontic treatment
- ▣ Dentoalveolar trauma
- ▣ Internal and external root resorption
- ▣ Presurgical case planning
- ▣ Assessment of treatment outcome

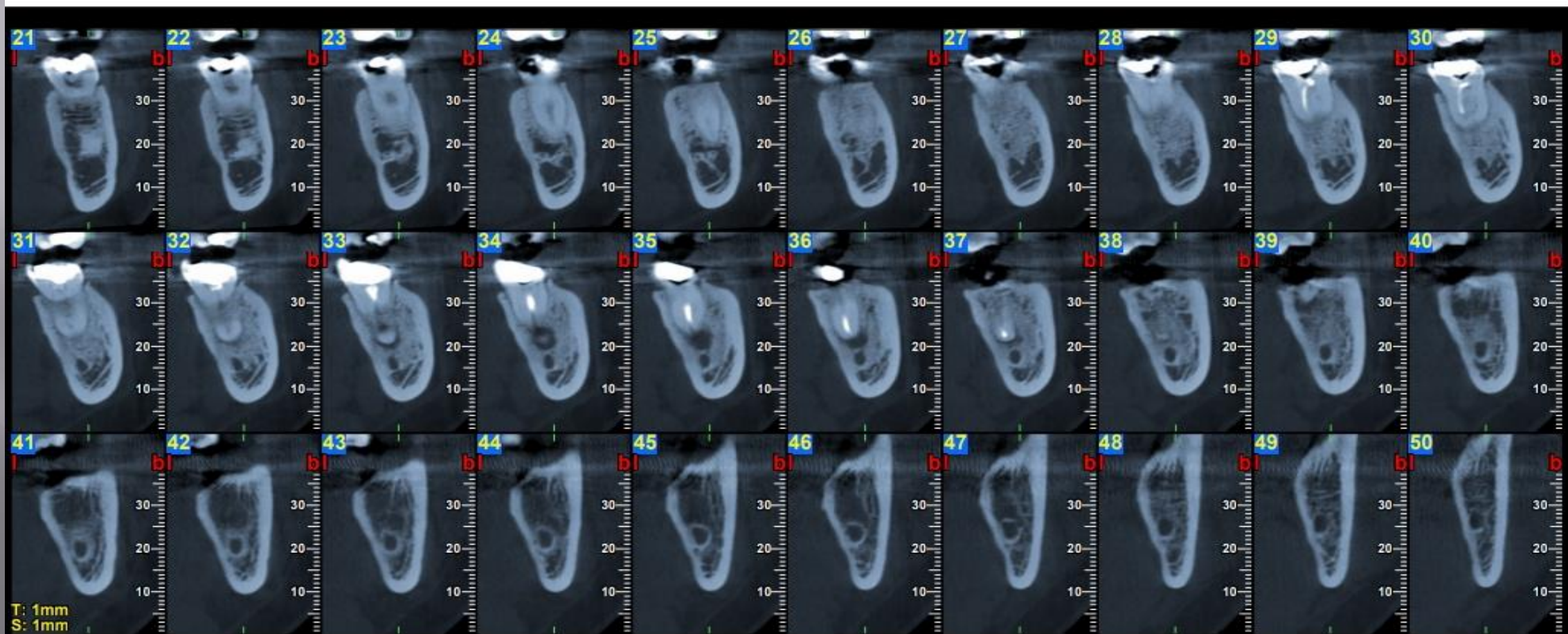
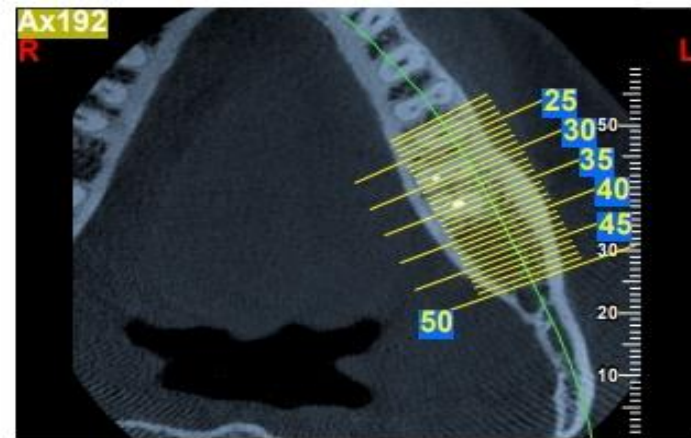
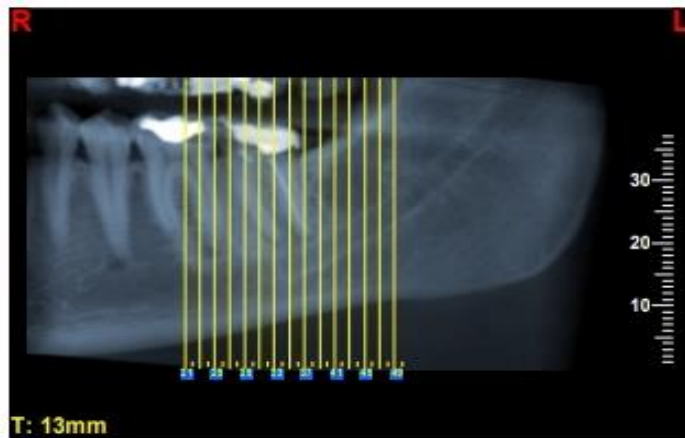
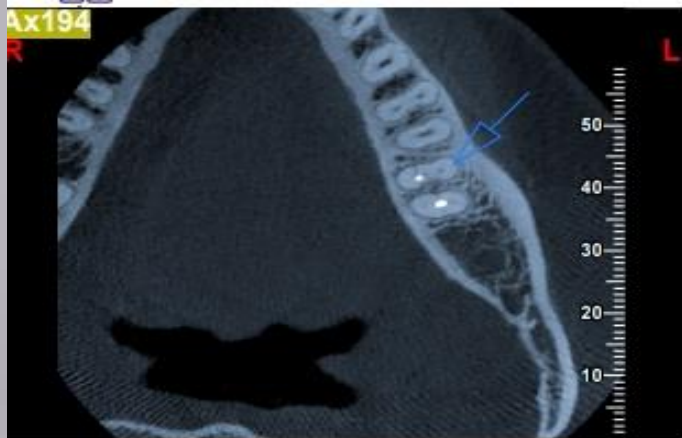
# Differential diagnosis





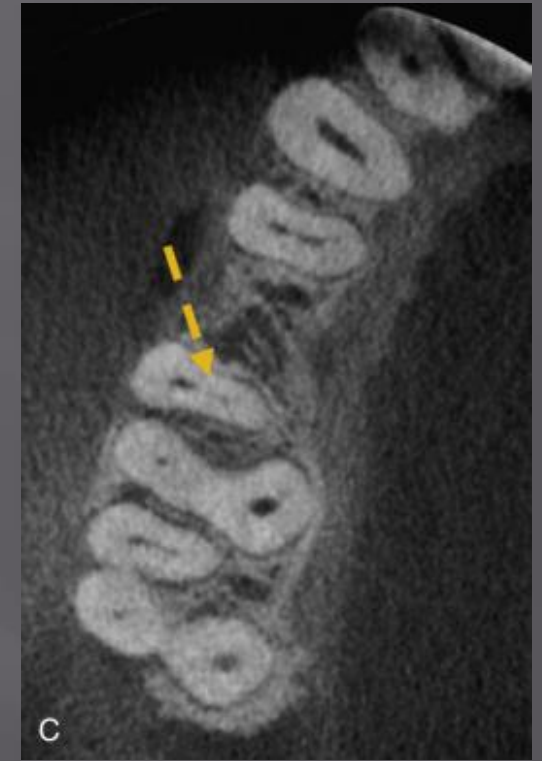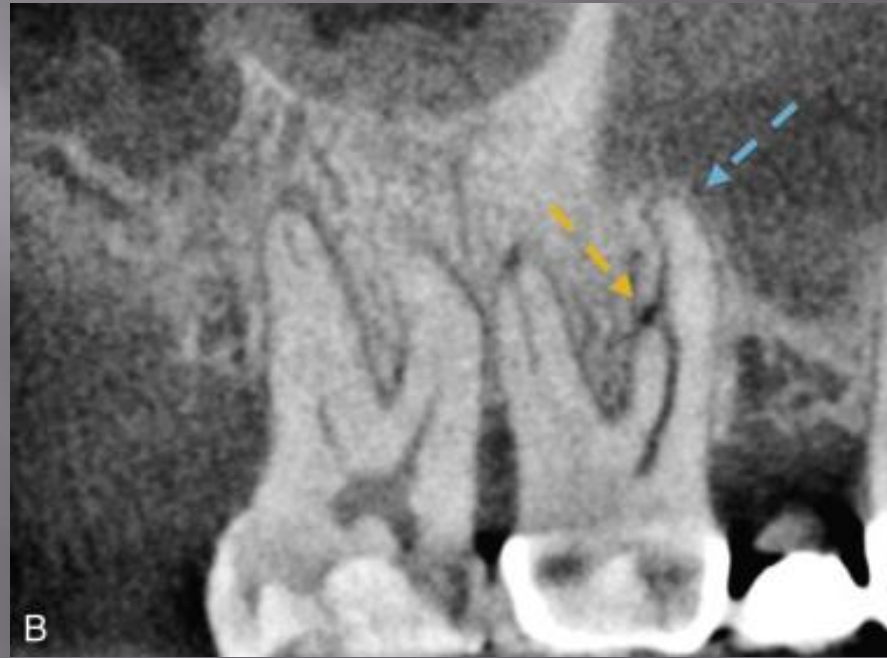
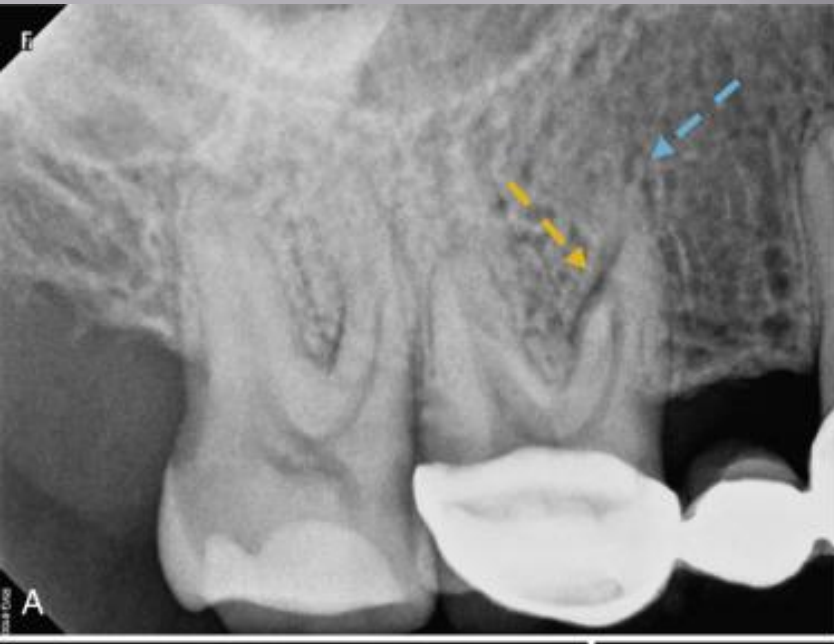


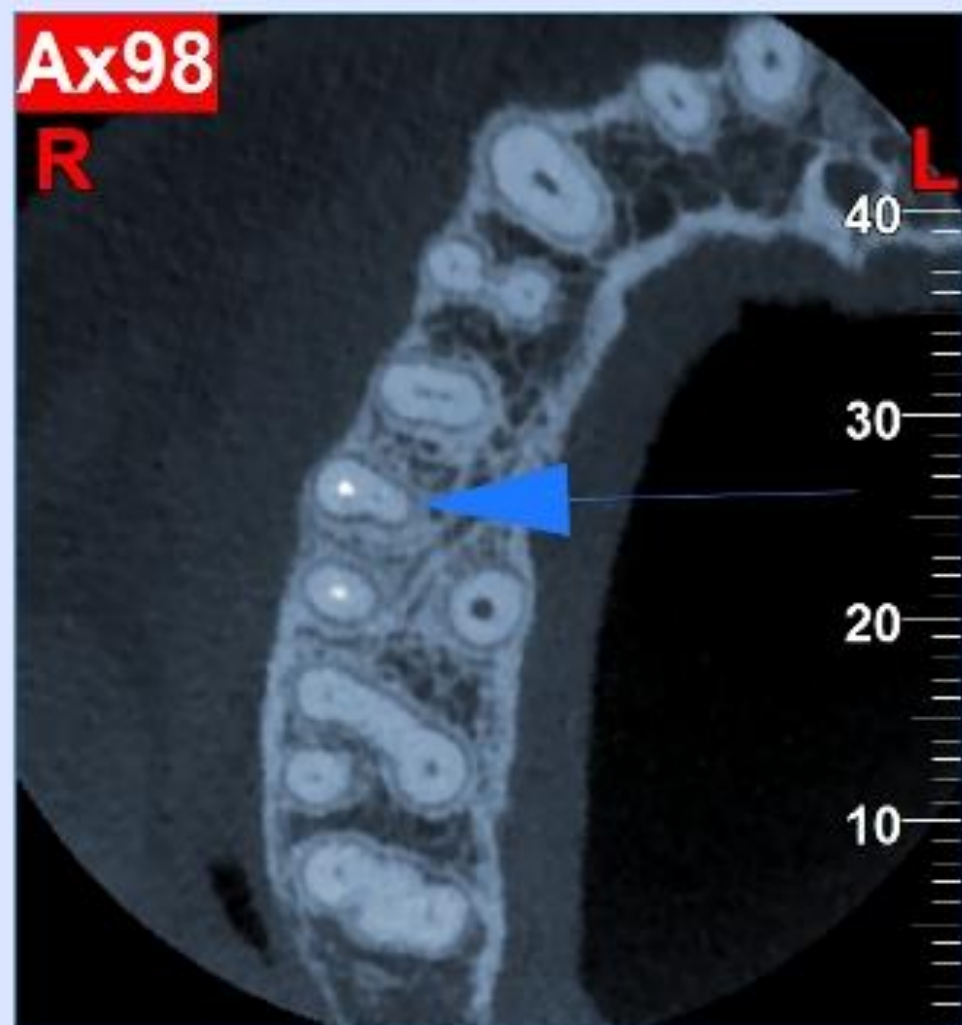
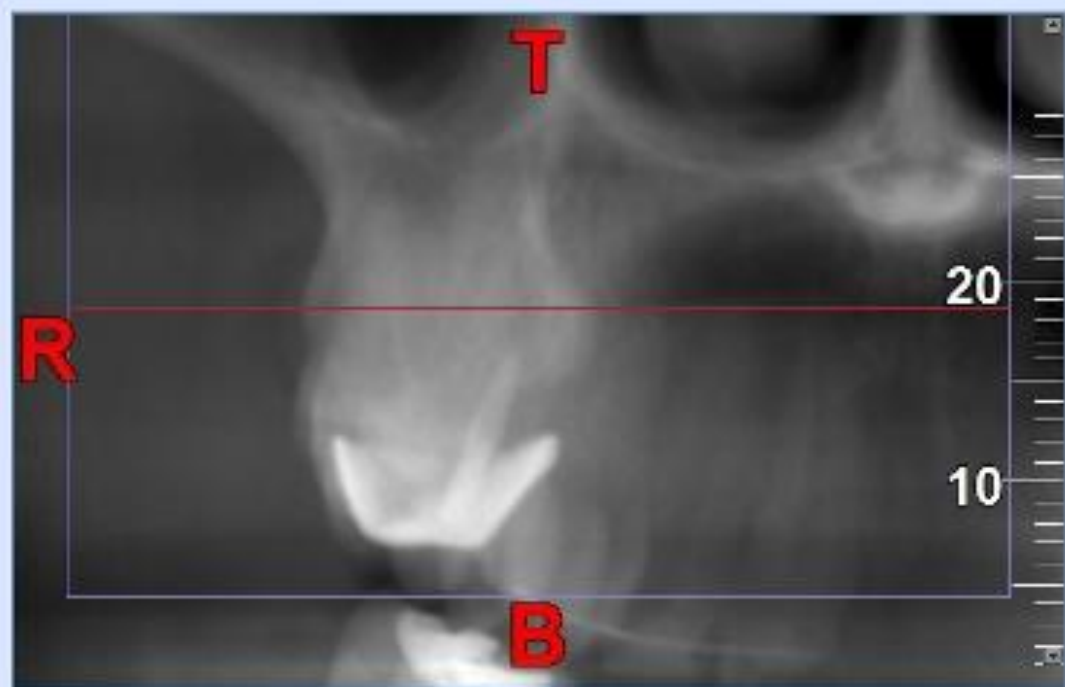
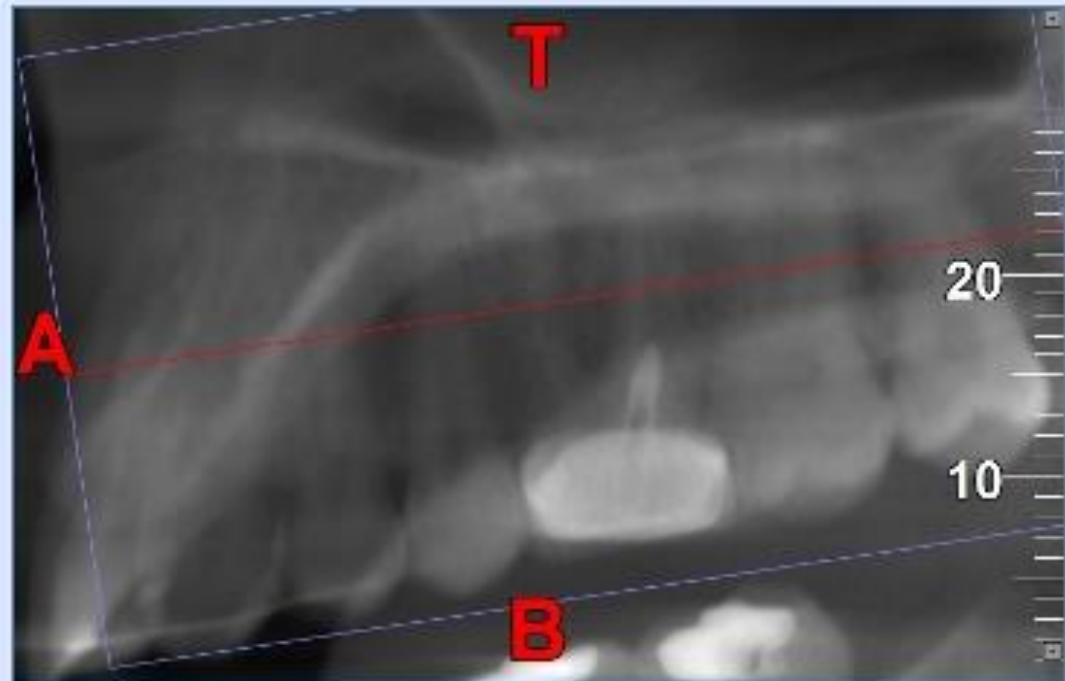


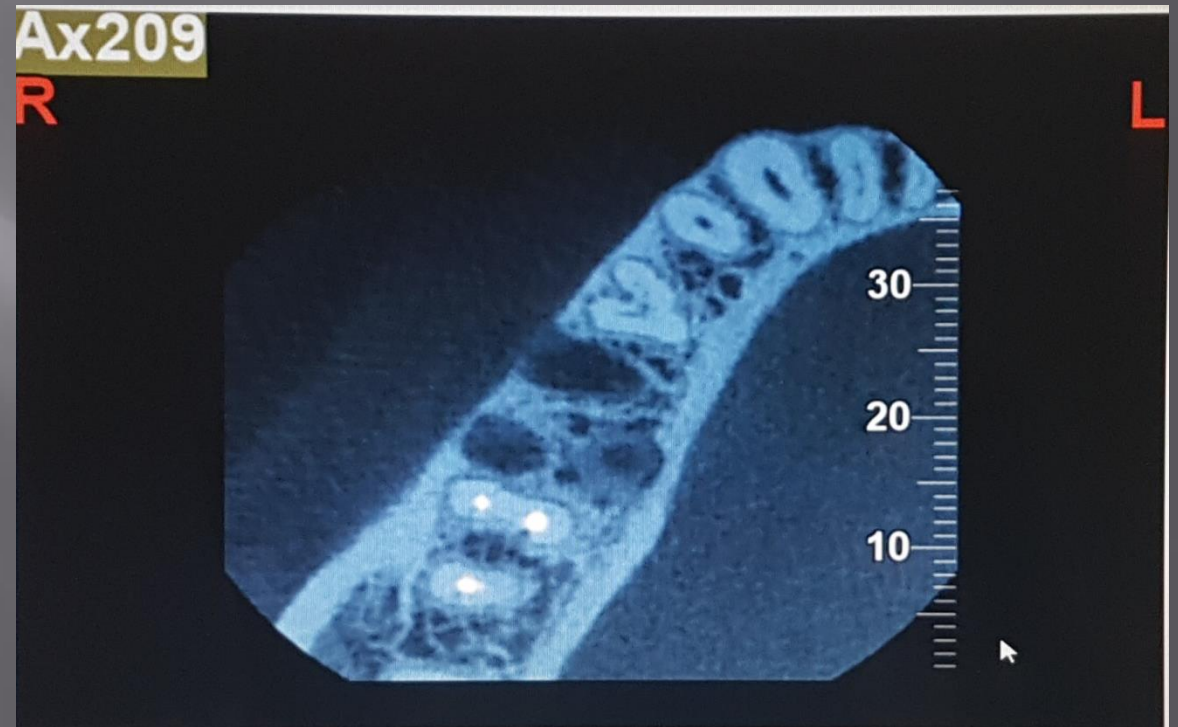
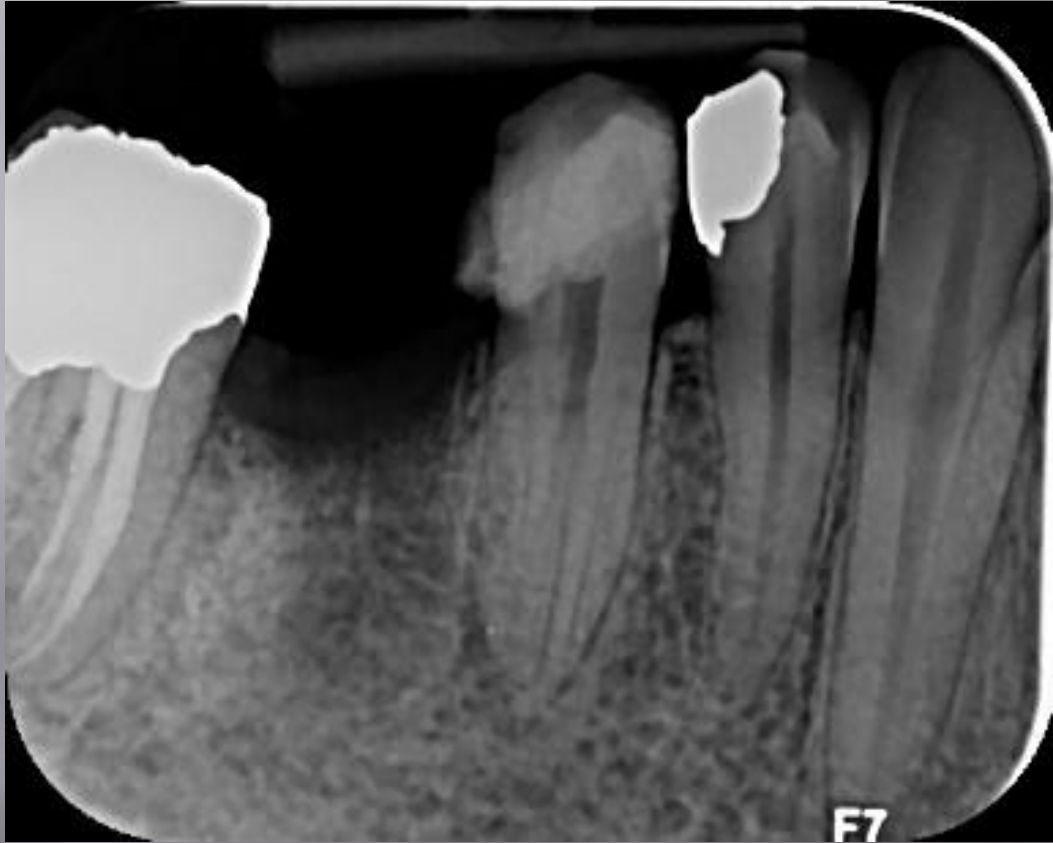


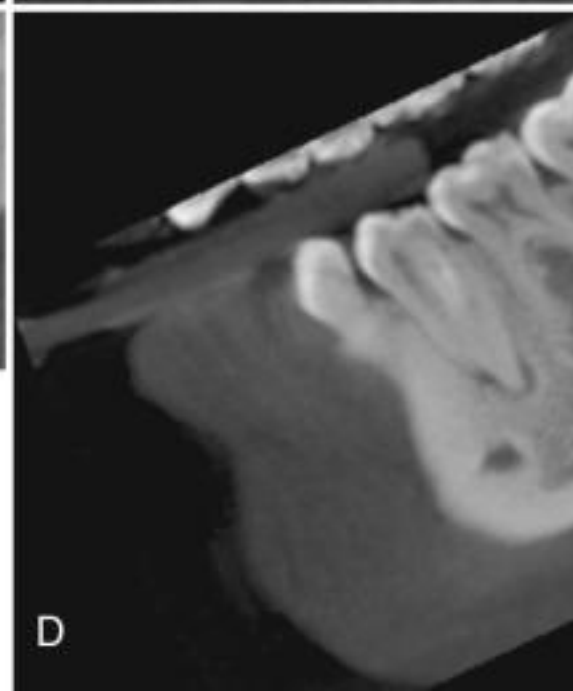
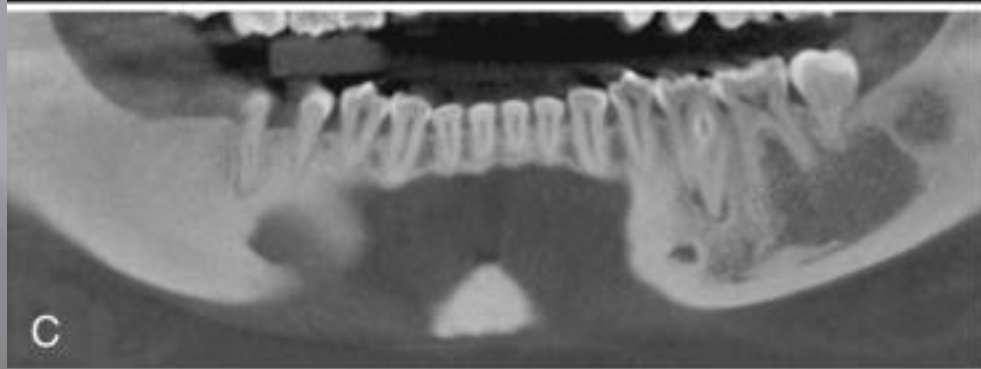
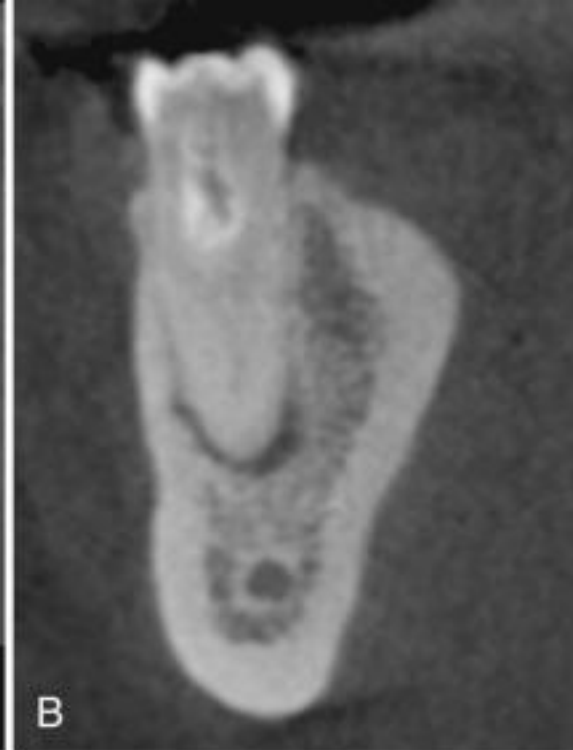
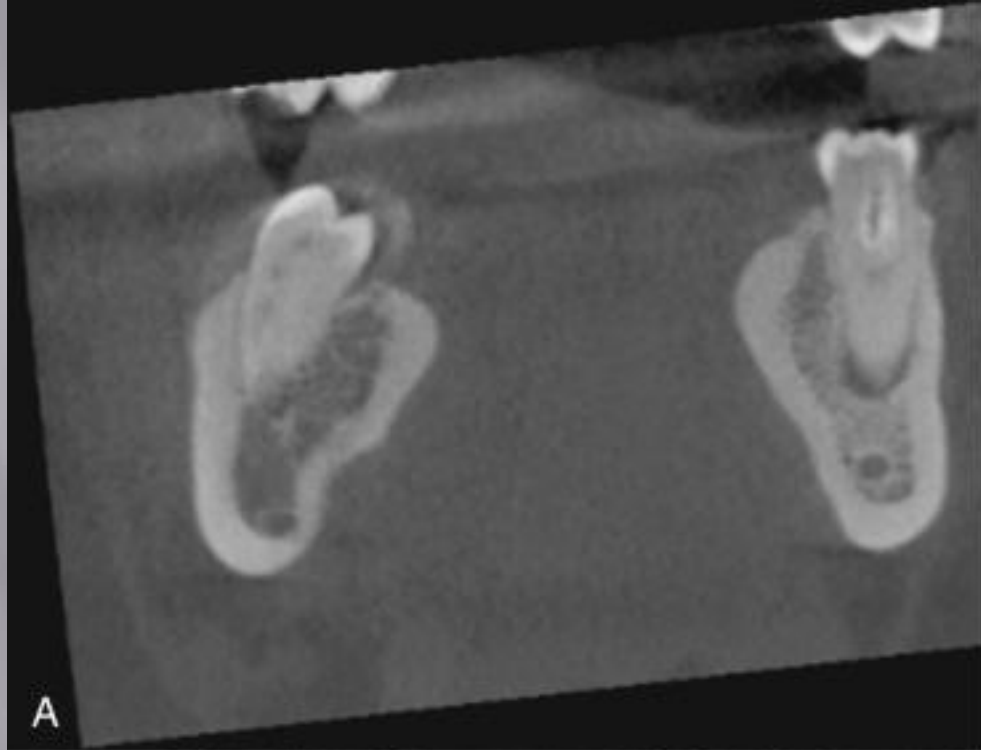


# Complex anatomy

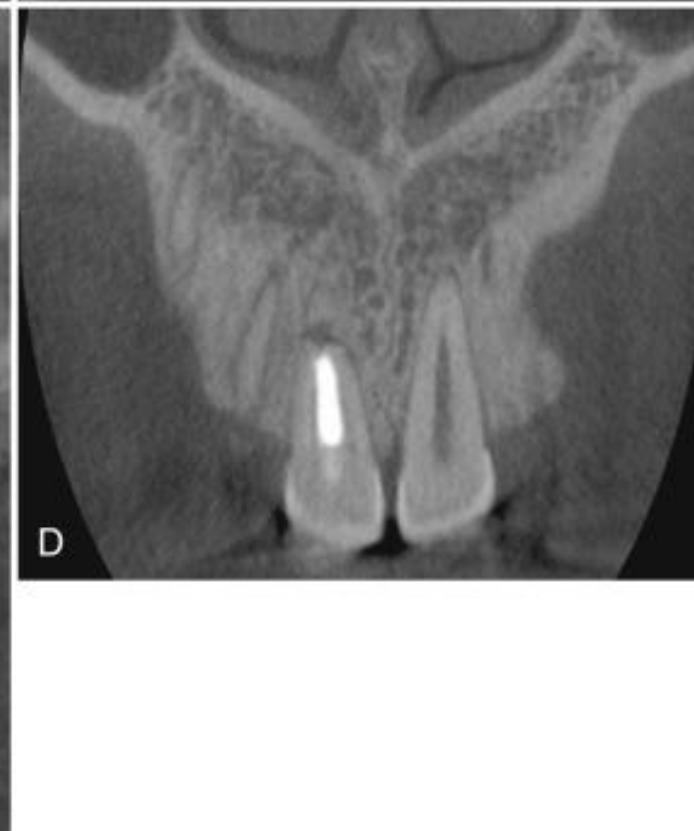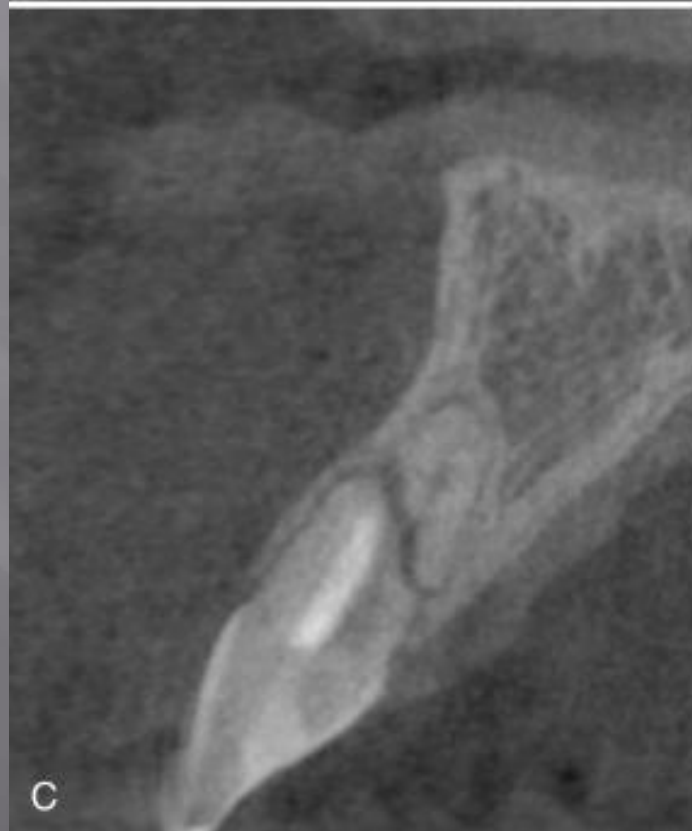
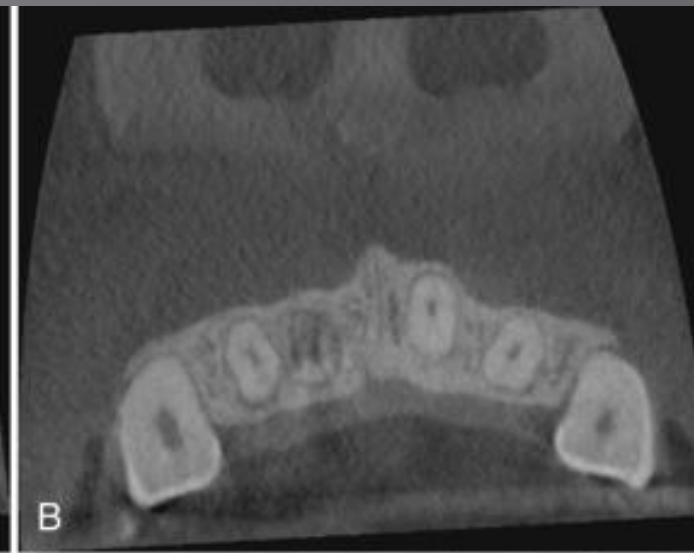

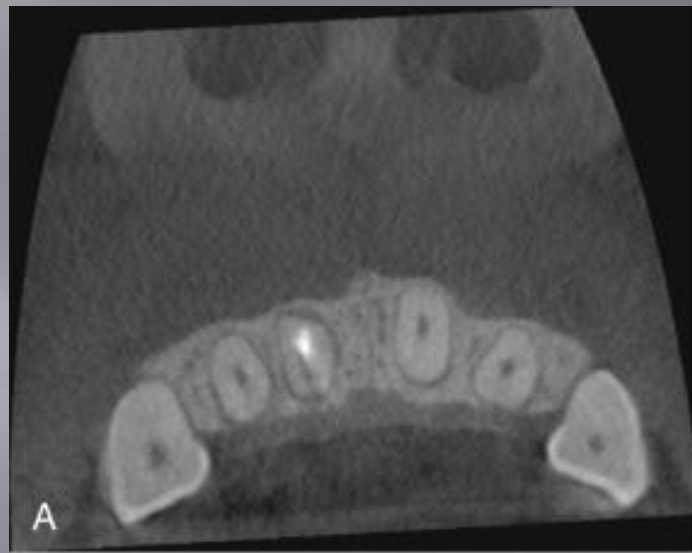
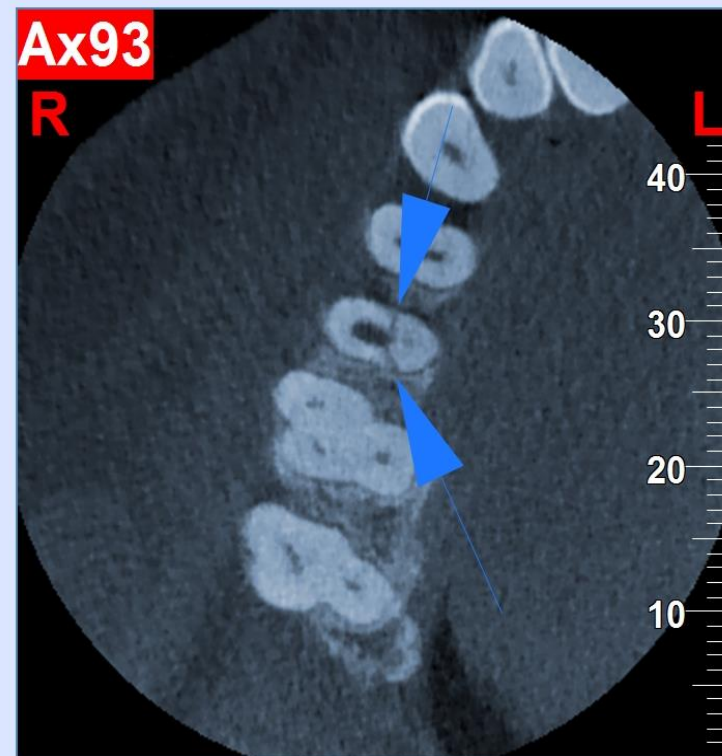


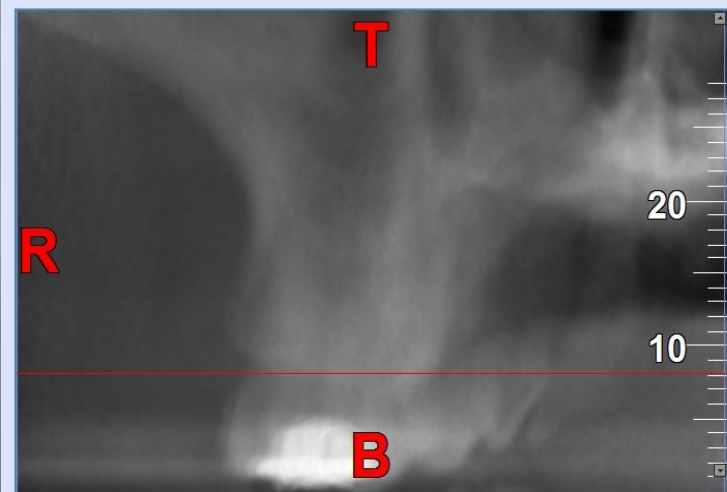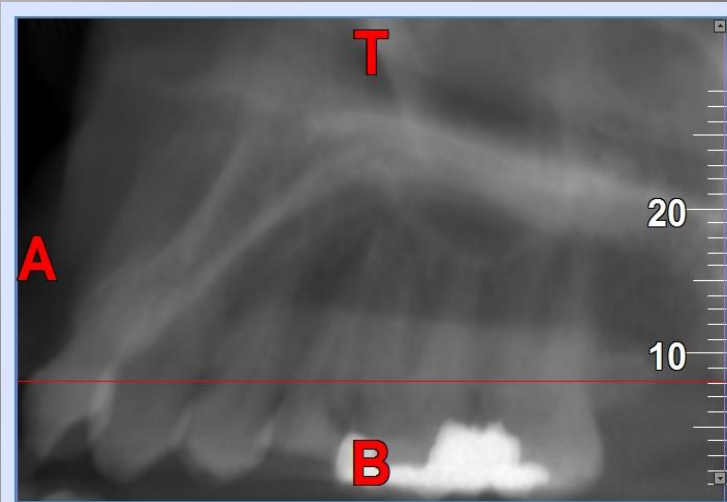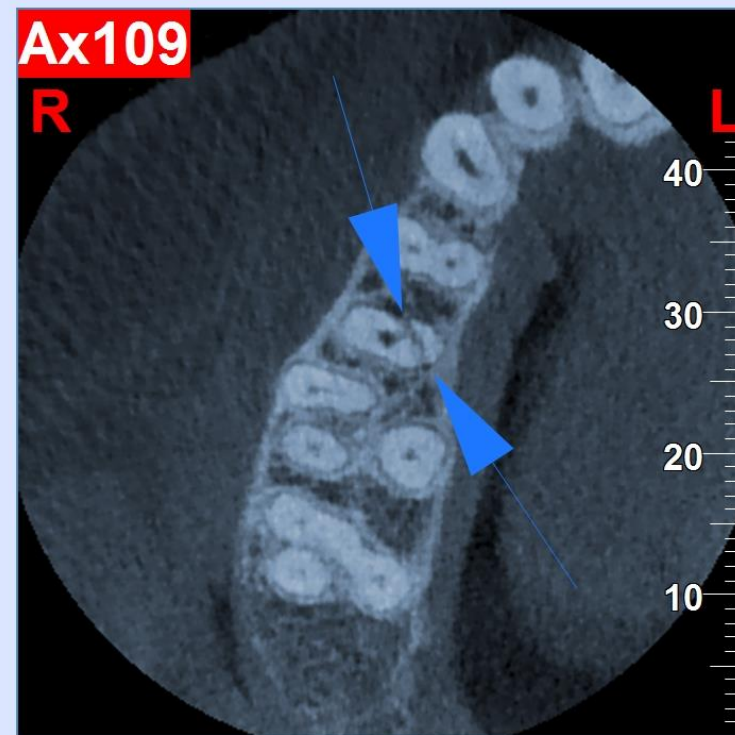




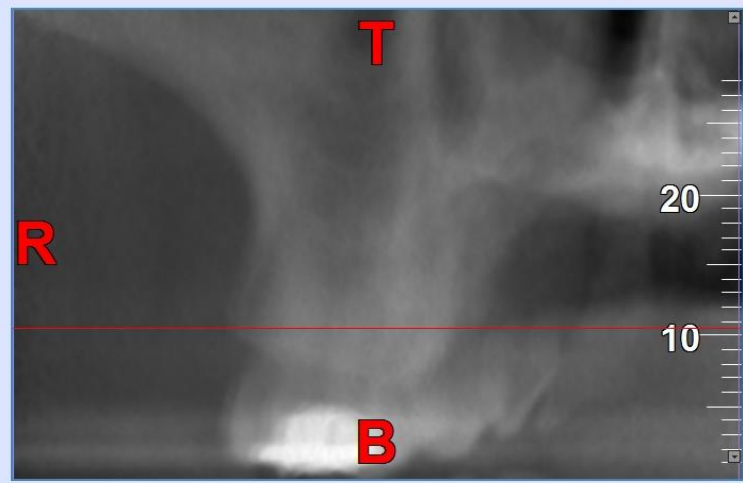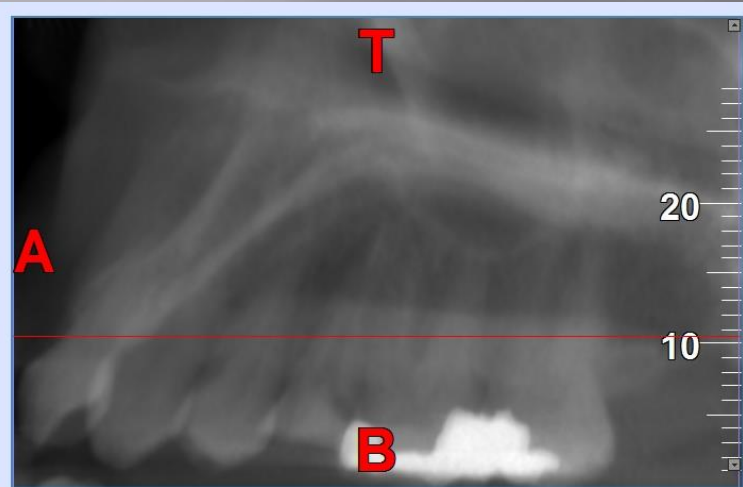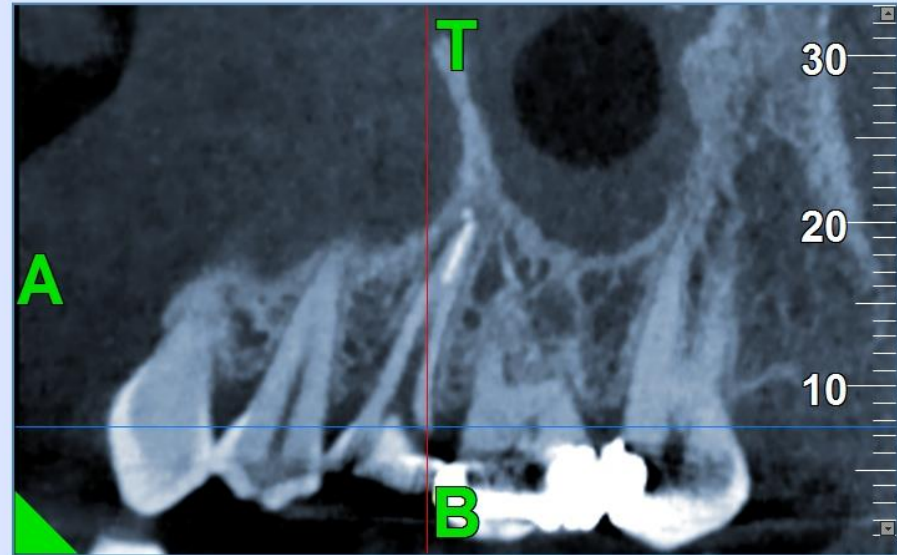
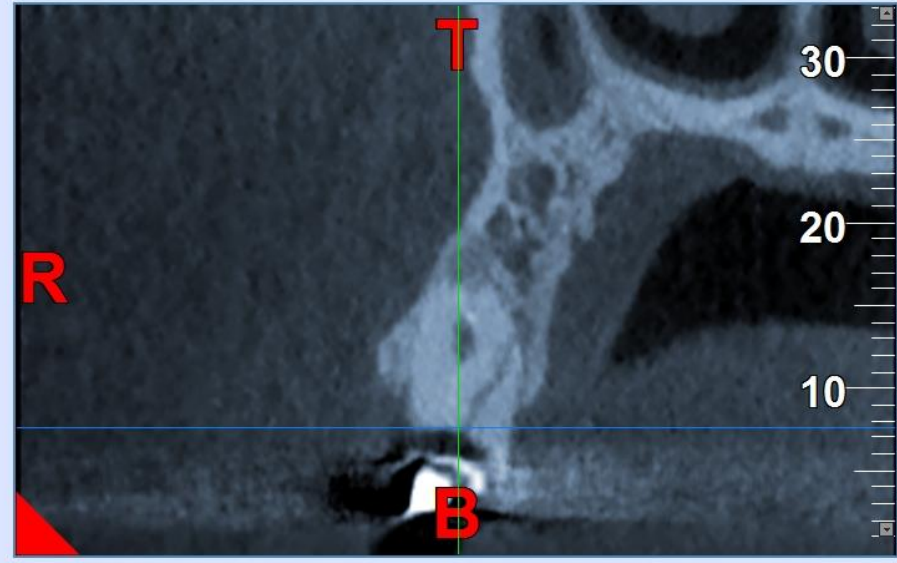
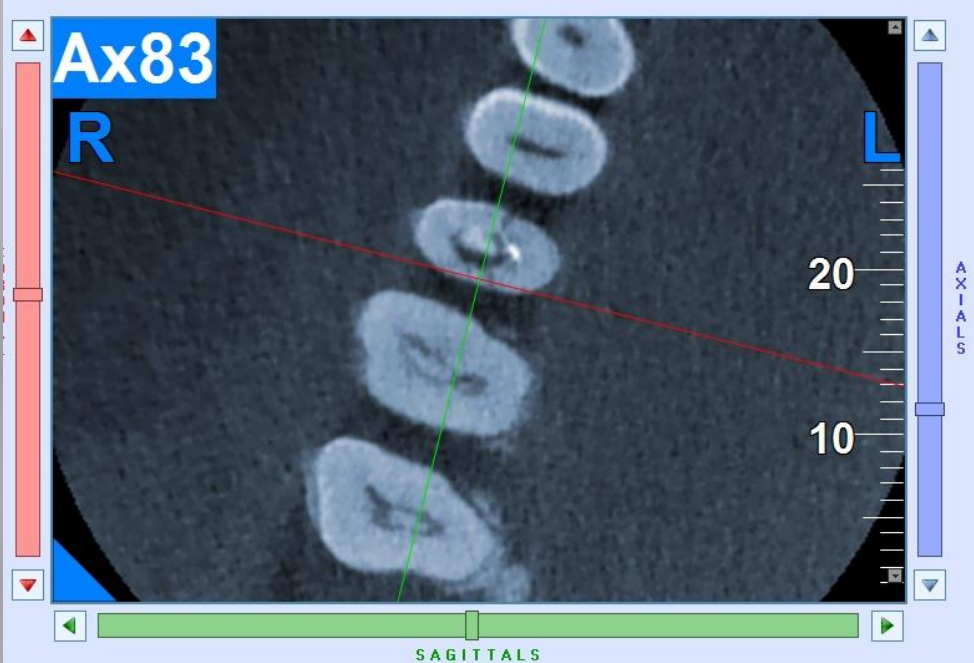
# Cracks and Fractures

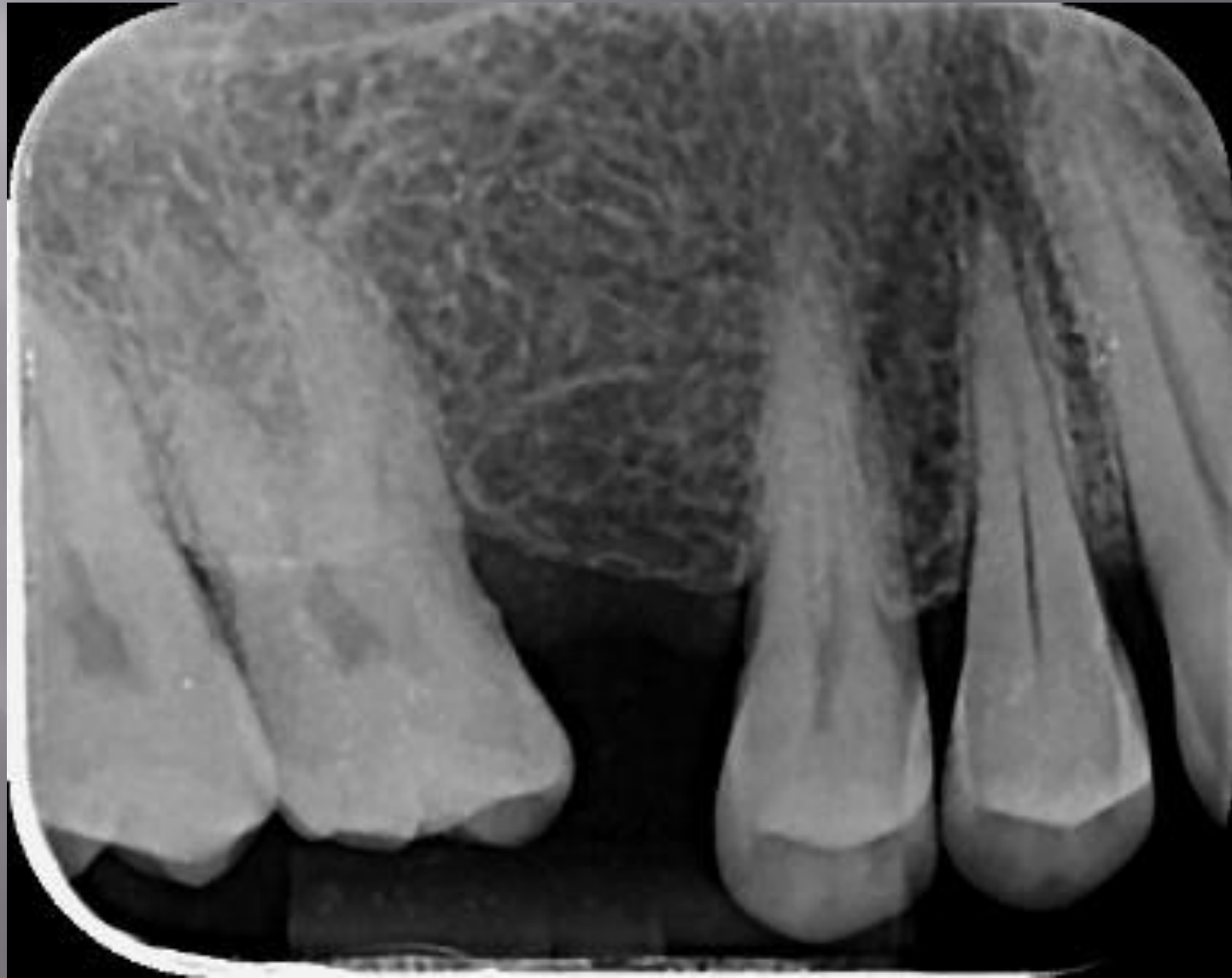

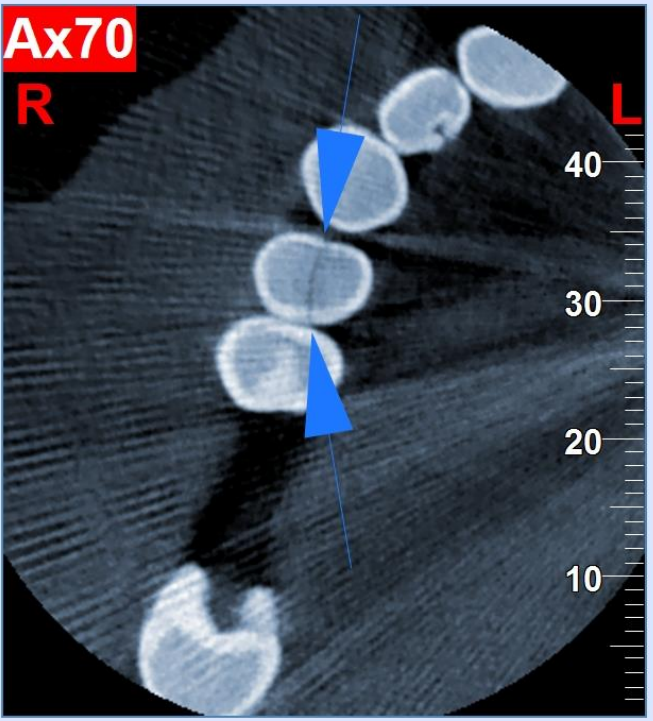
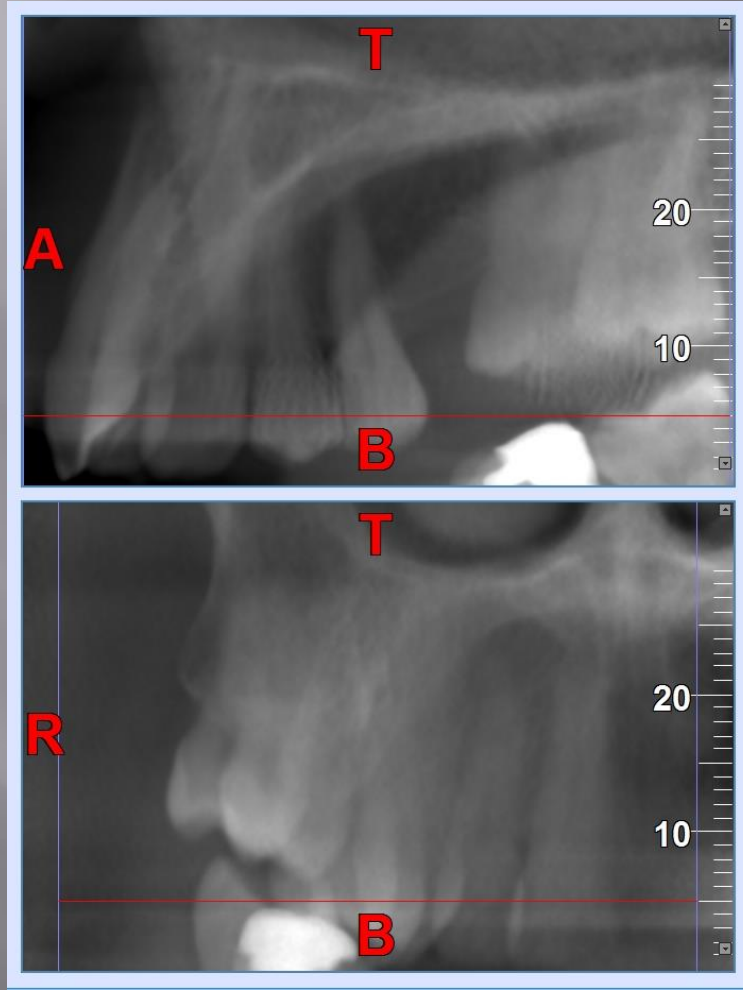


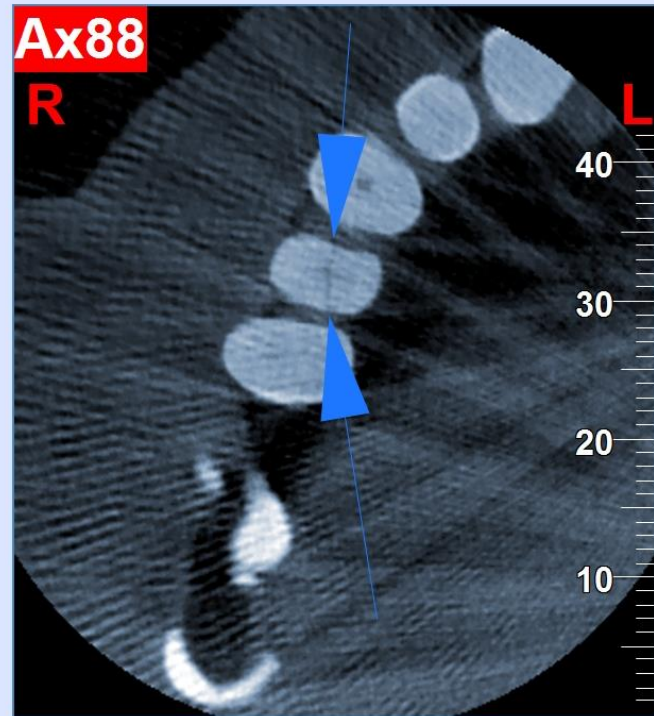

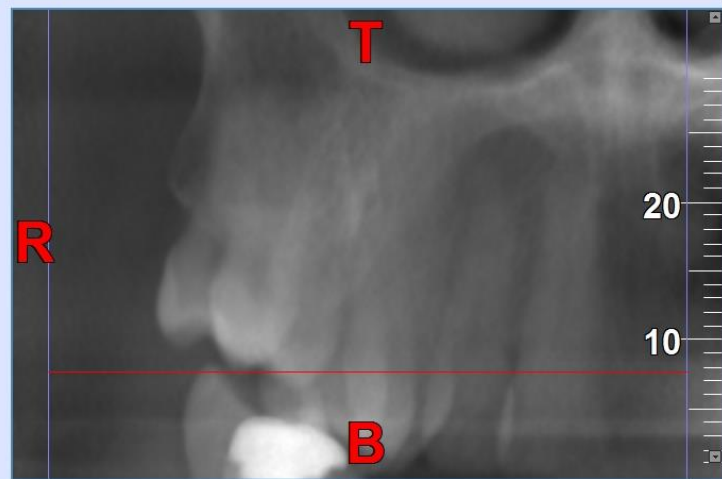
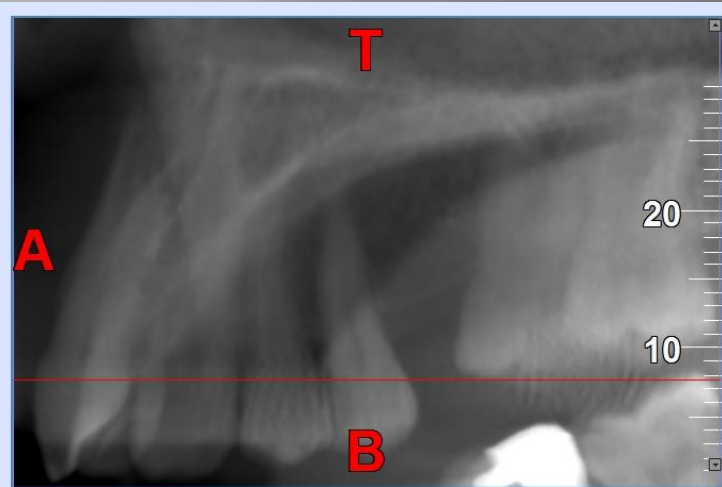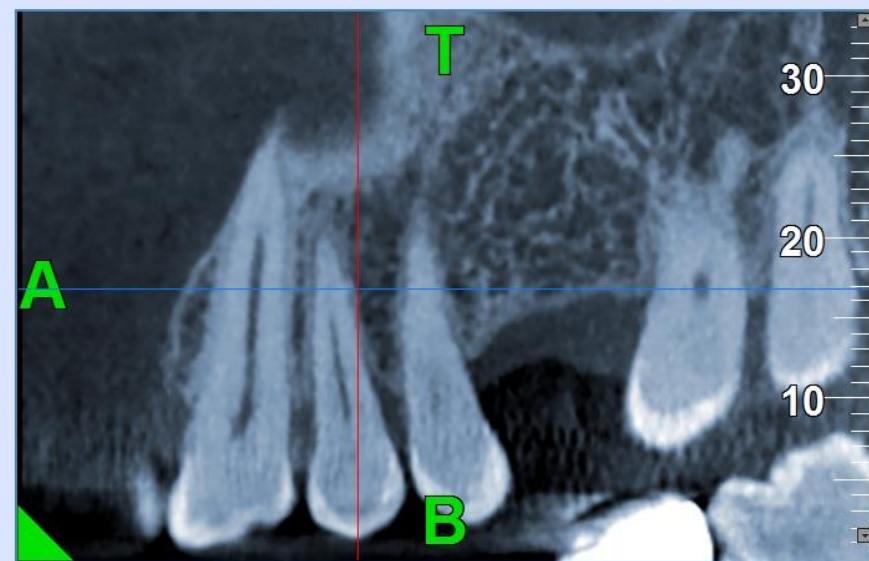
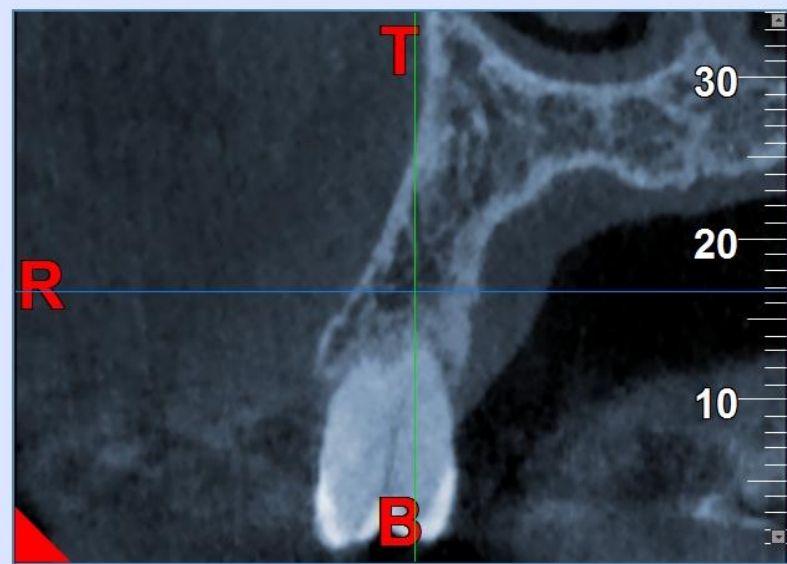
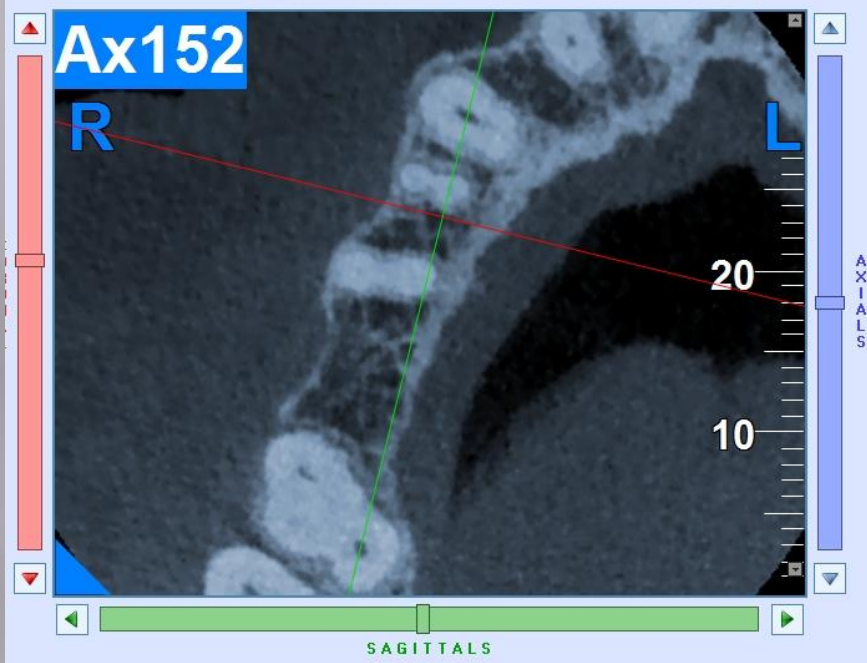




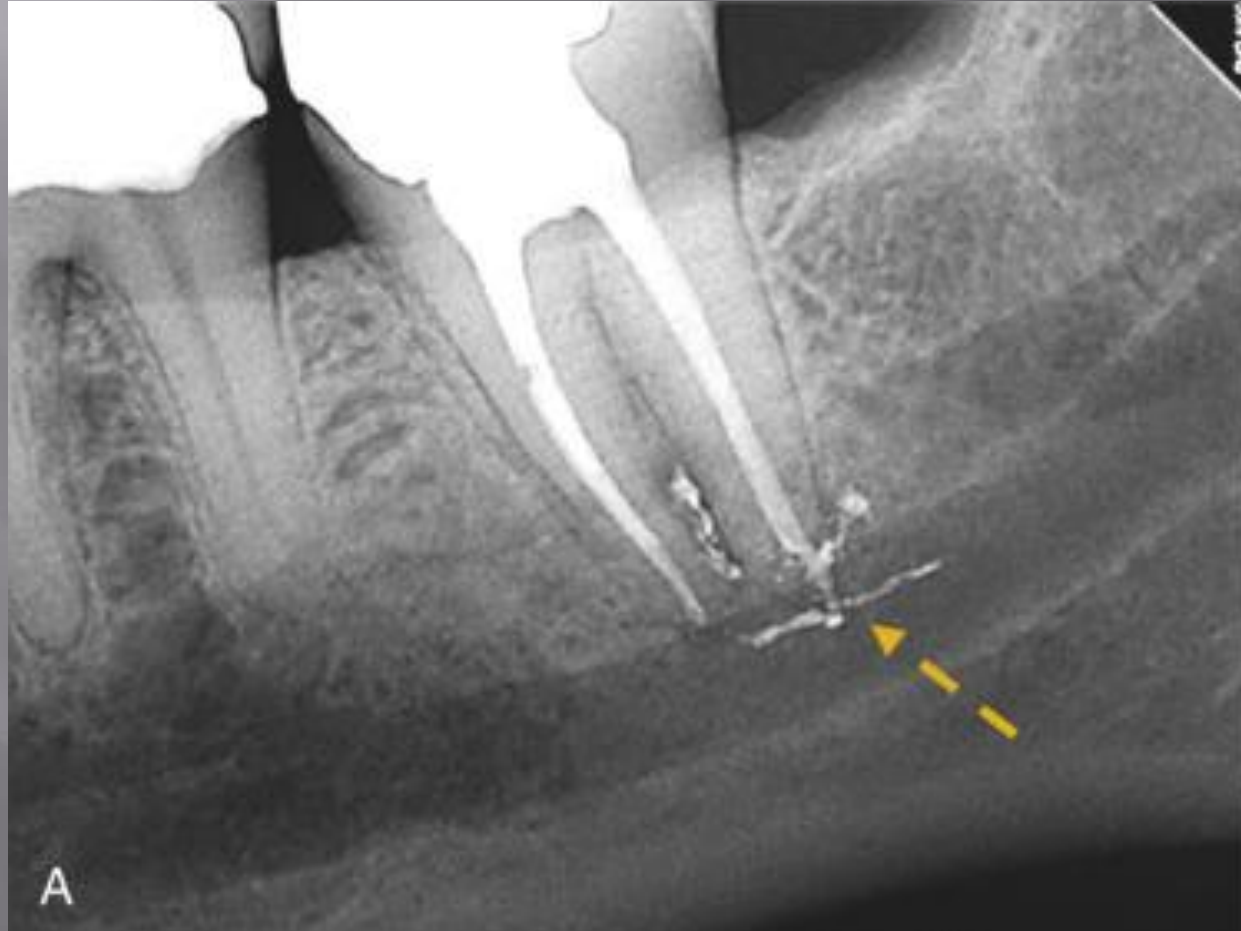


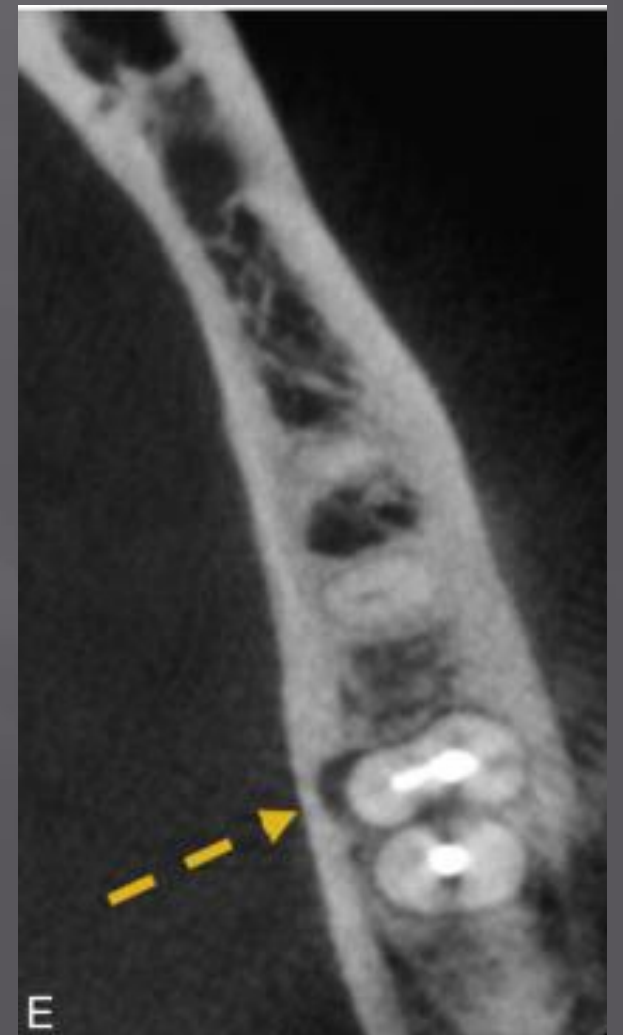
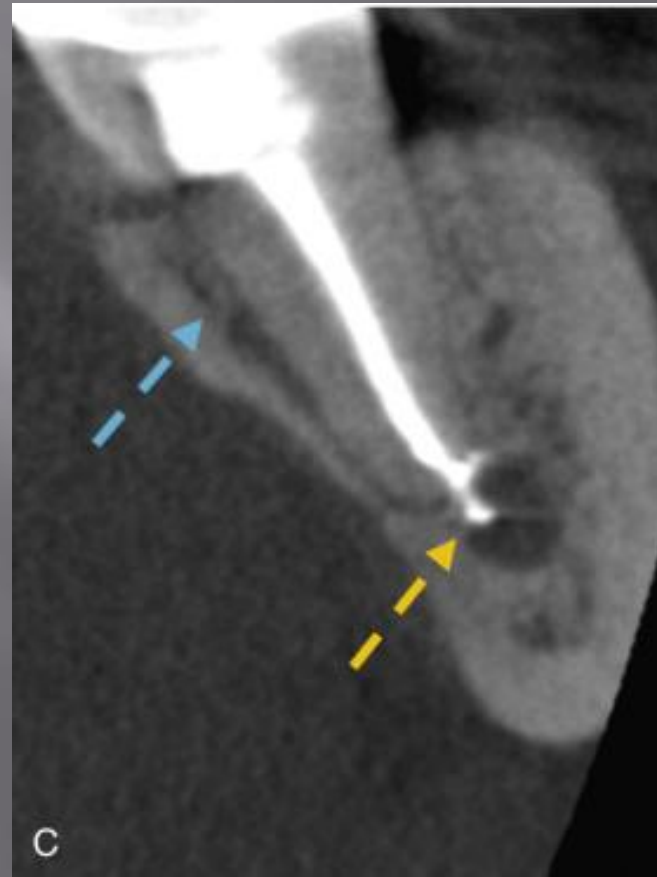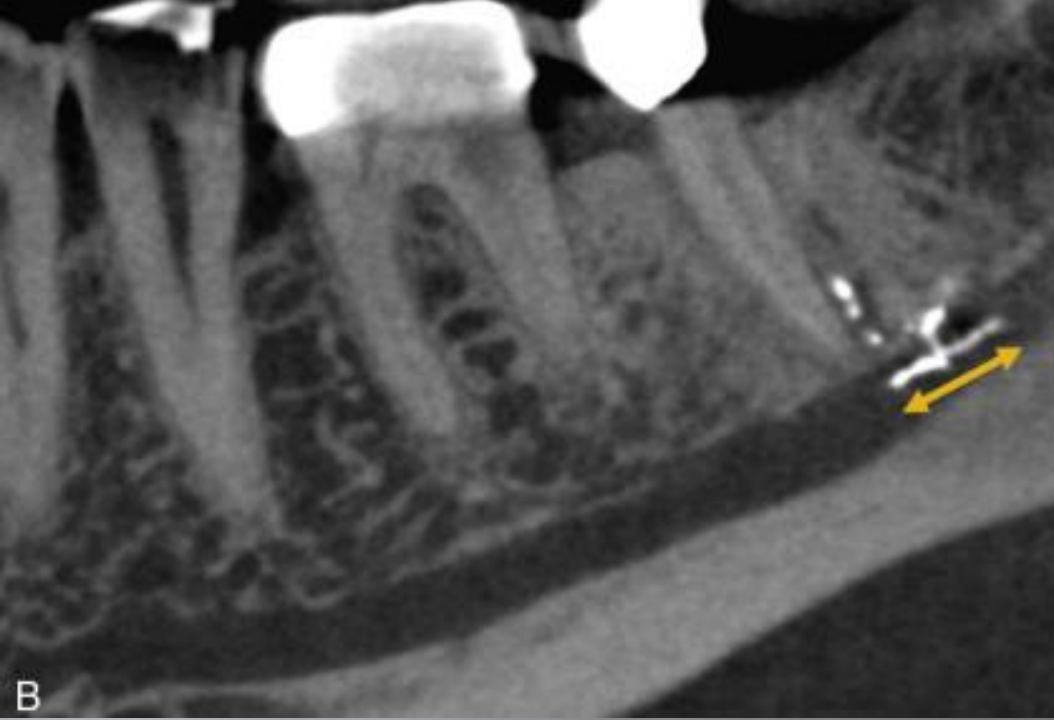




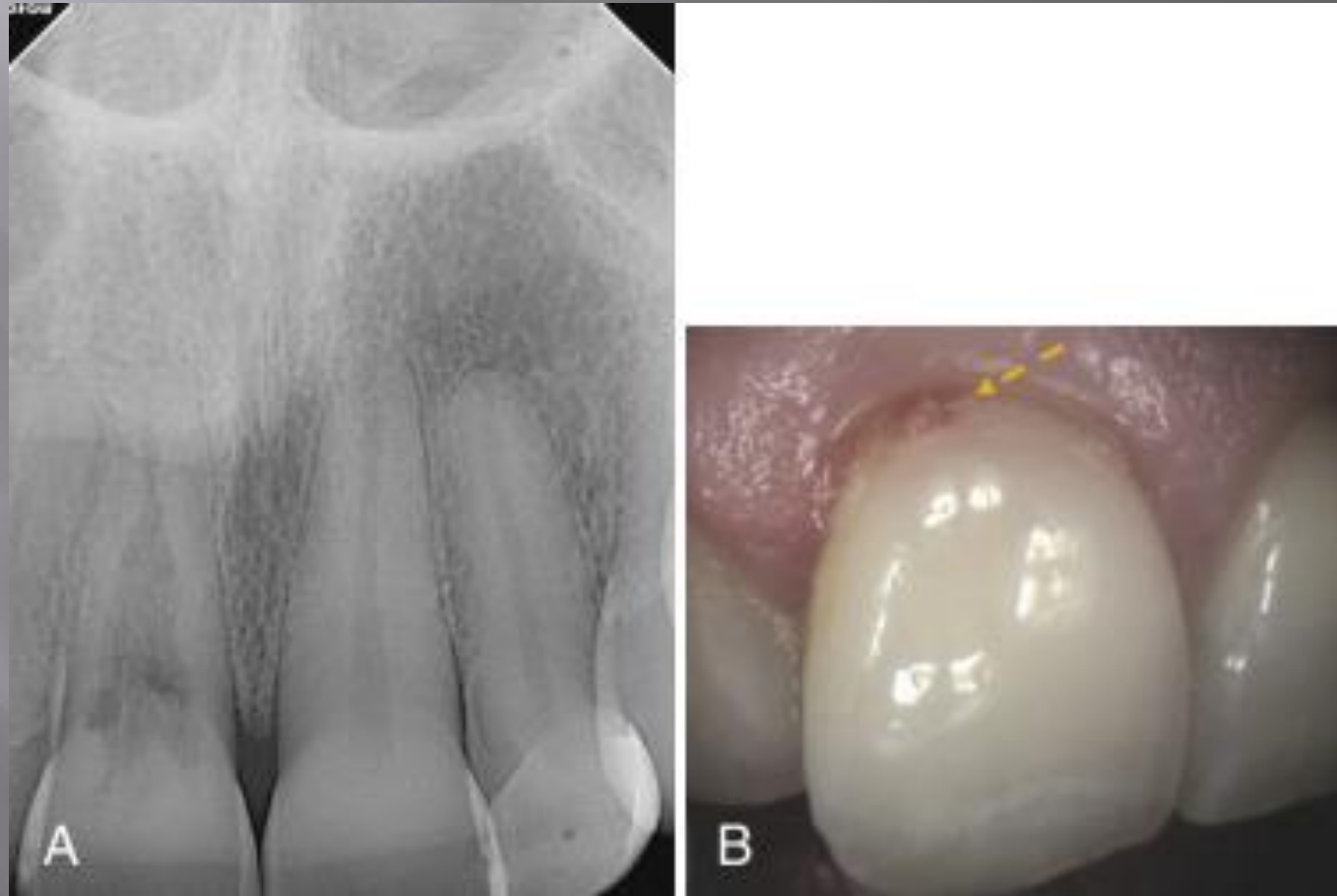


# Materials Extending Beyond The Canal

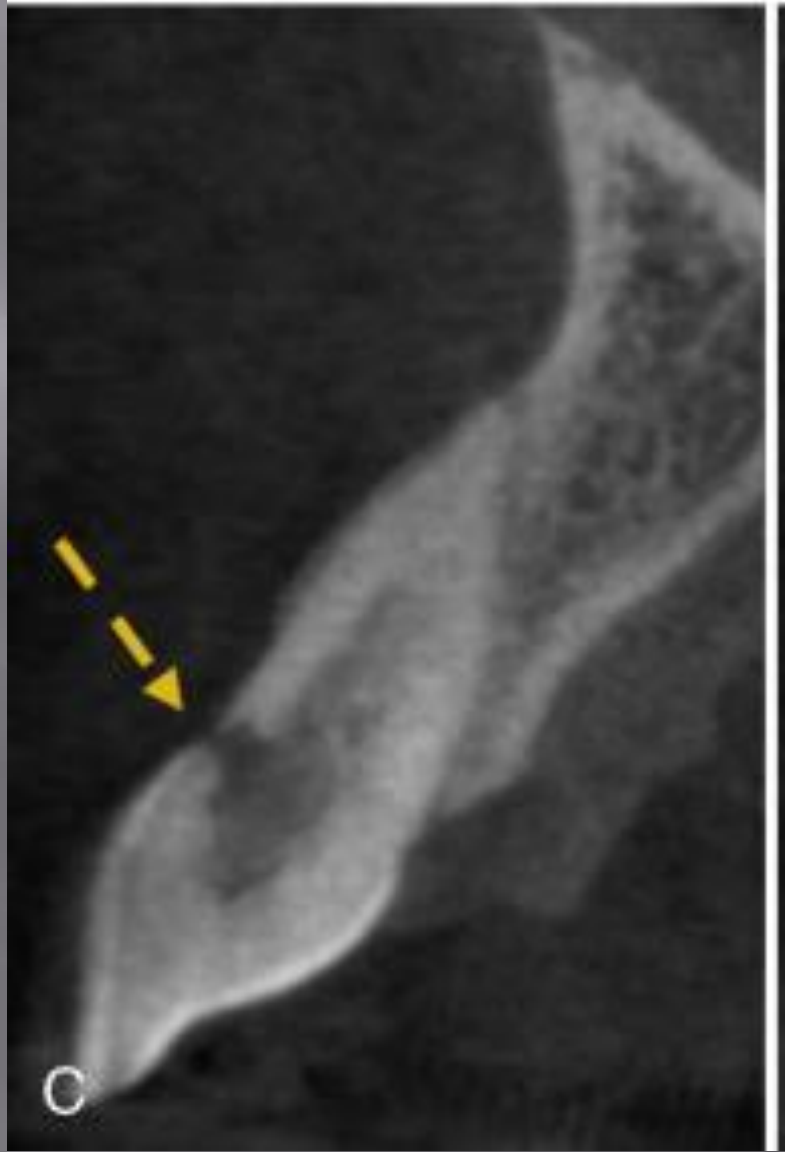

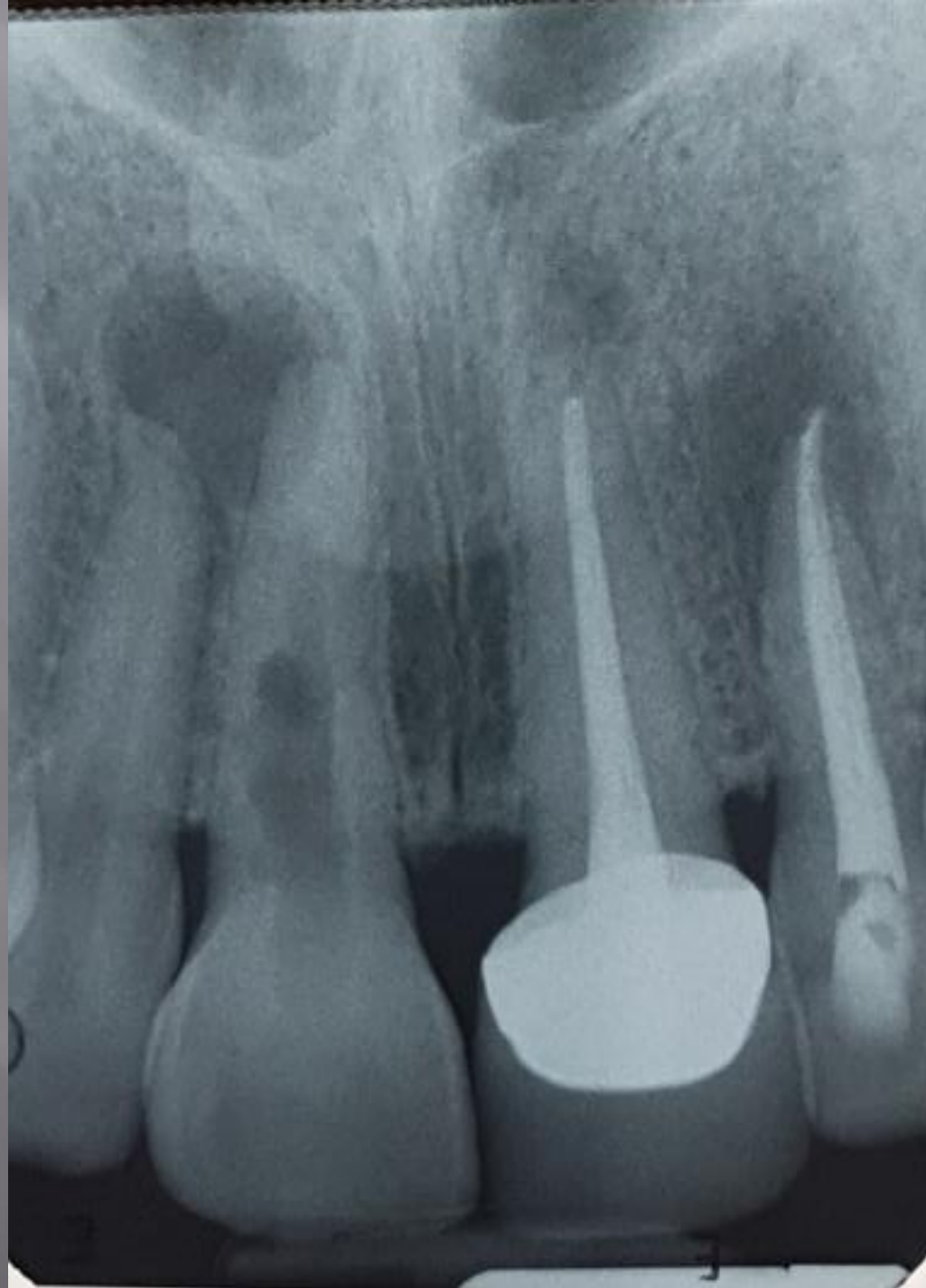


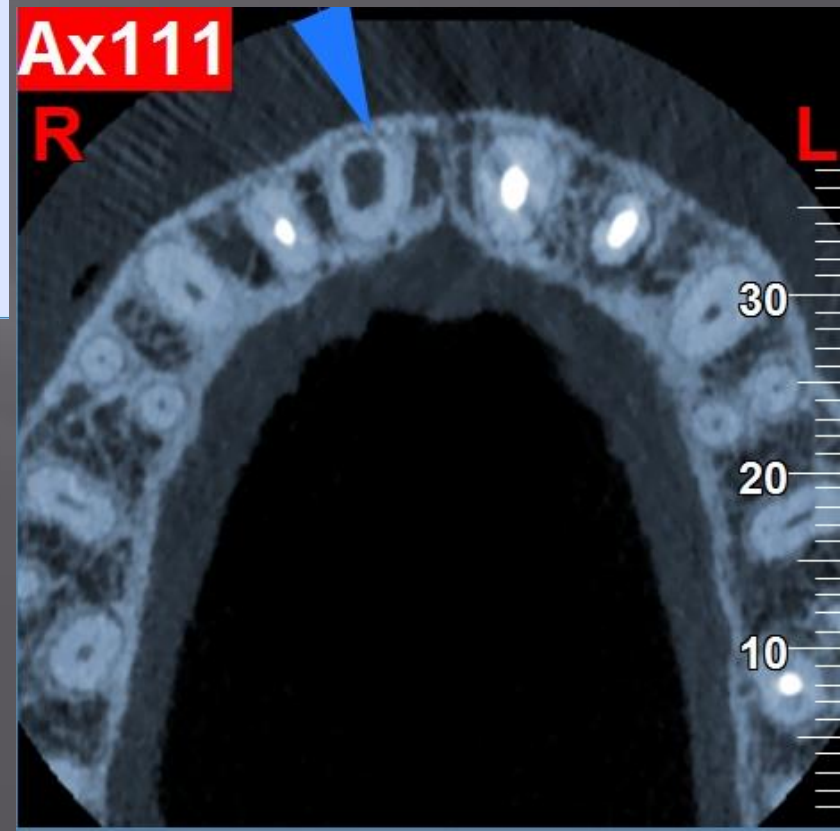
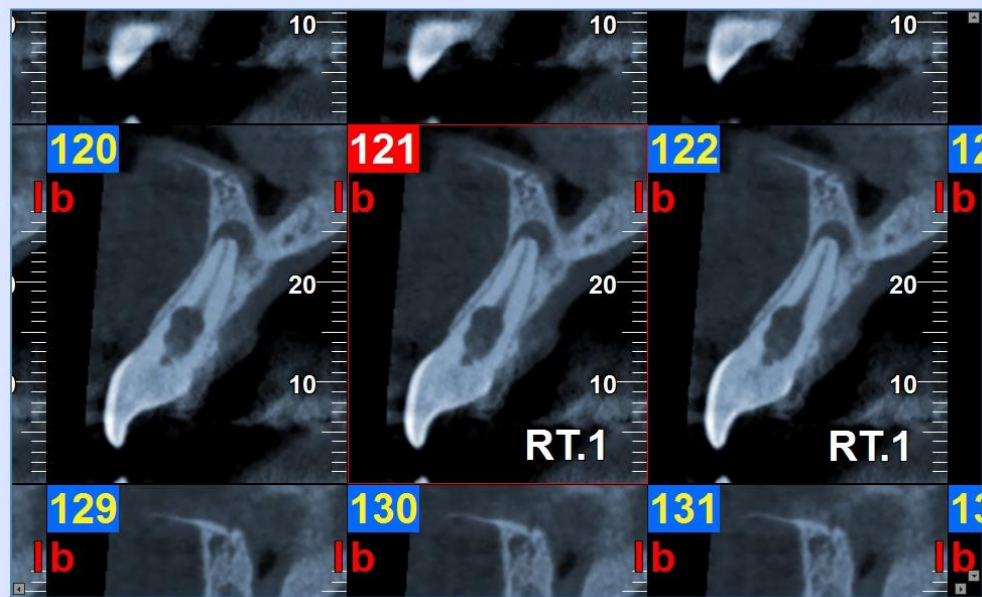
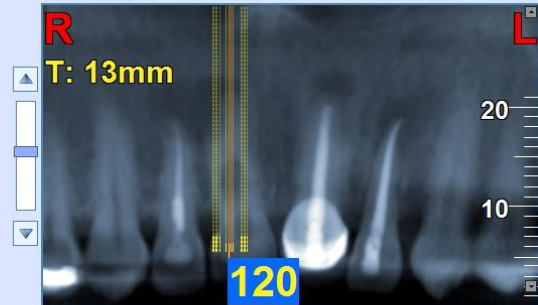
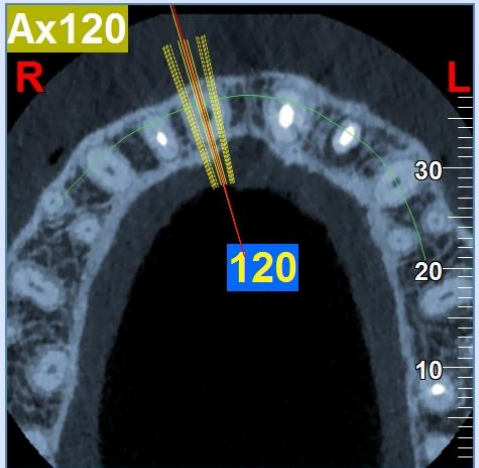
# External And Internal Root Resorption

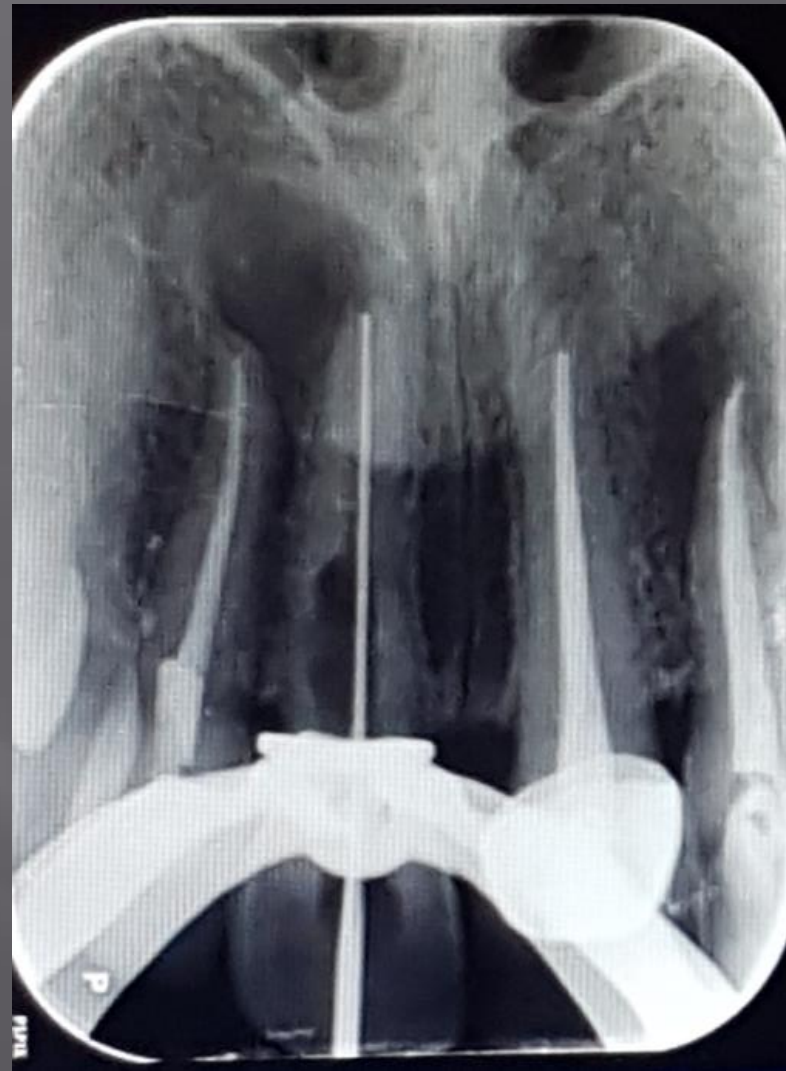
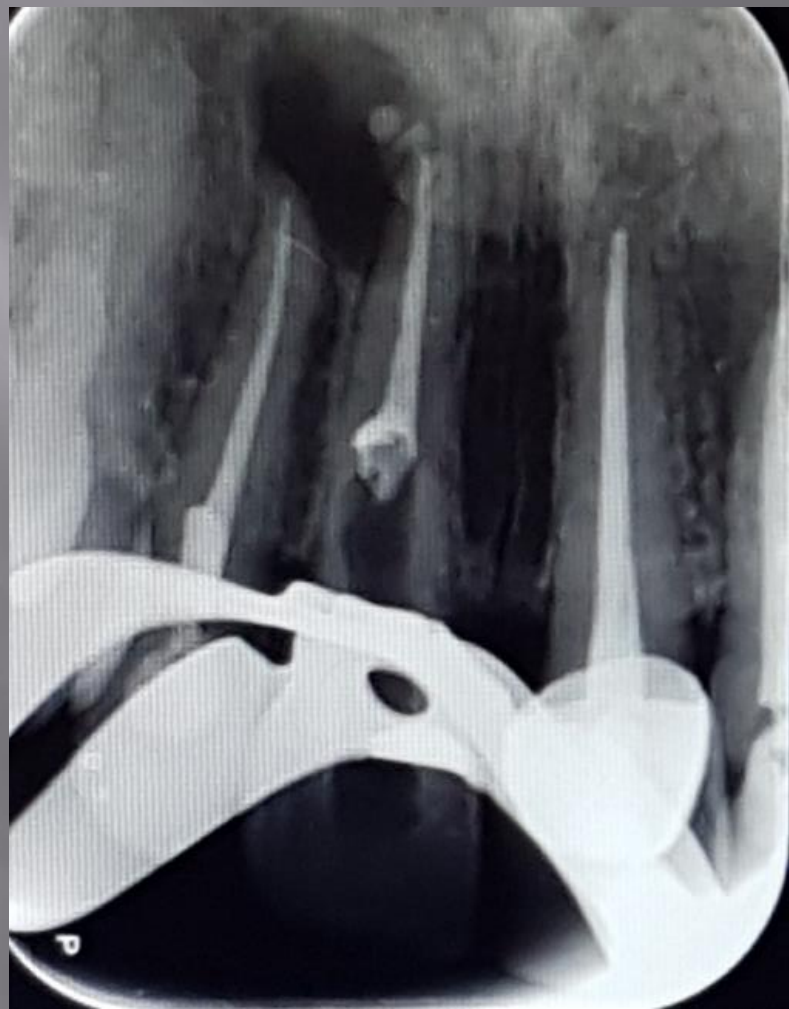
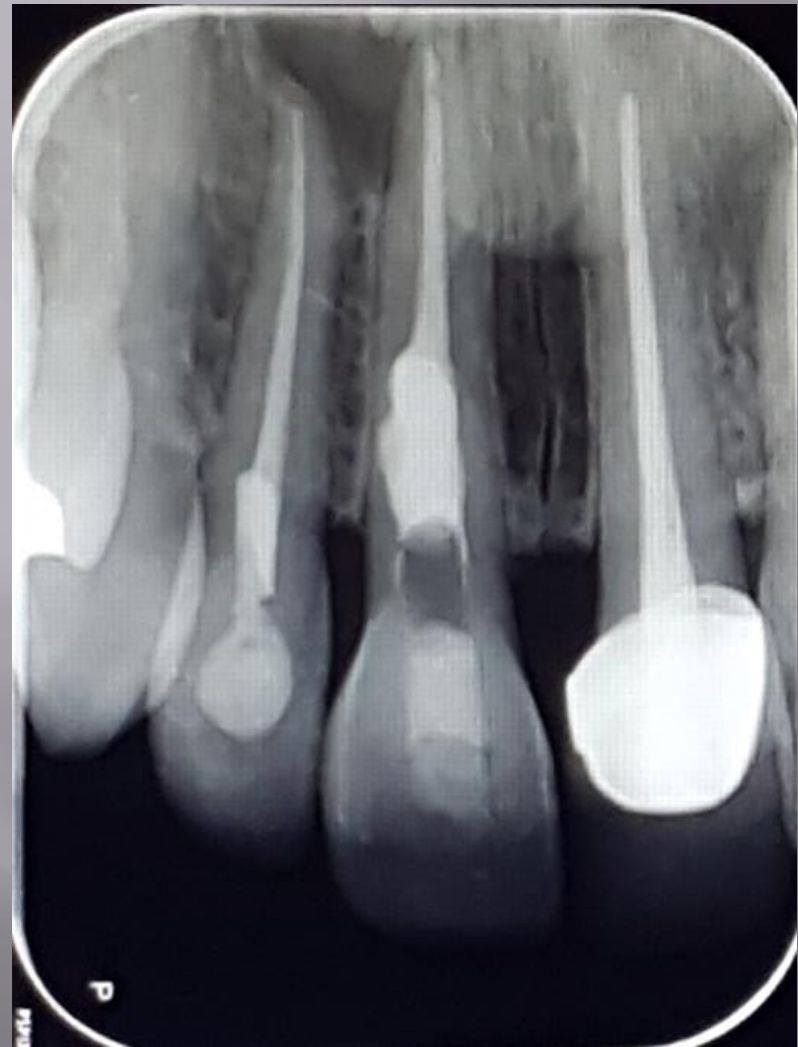




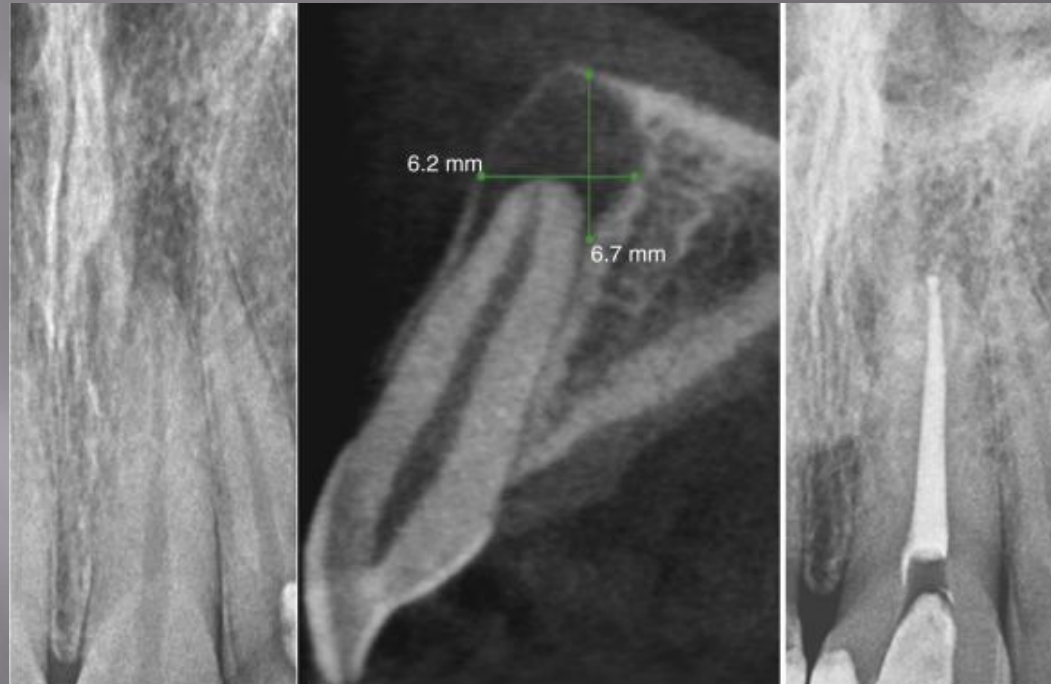







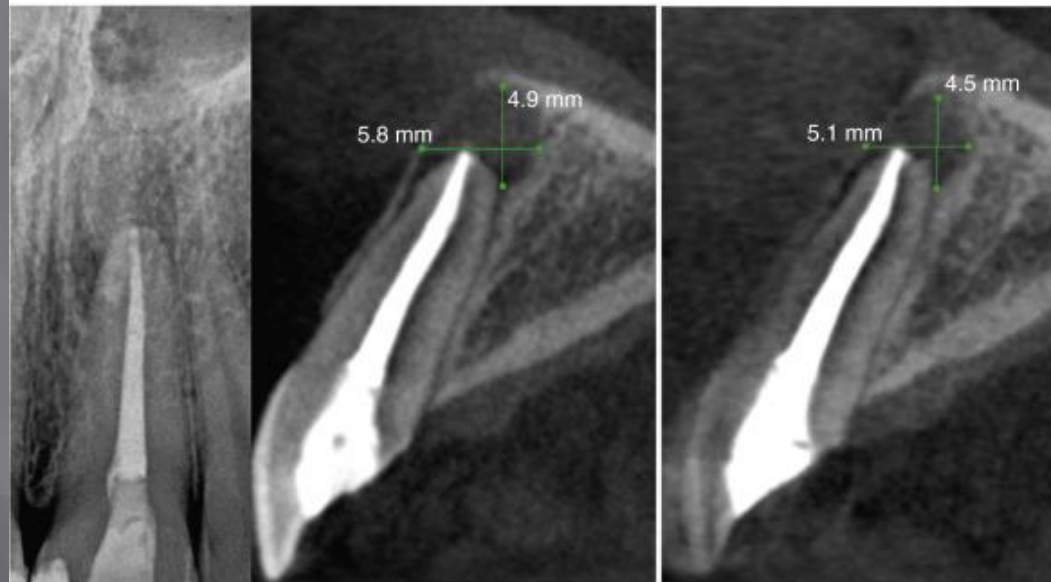
# Follow up



A 02-03-2011  
Initial PA

02-03-2011  
Initial corrected sagittal view

B 02-14-2011  
Obturation PA



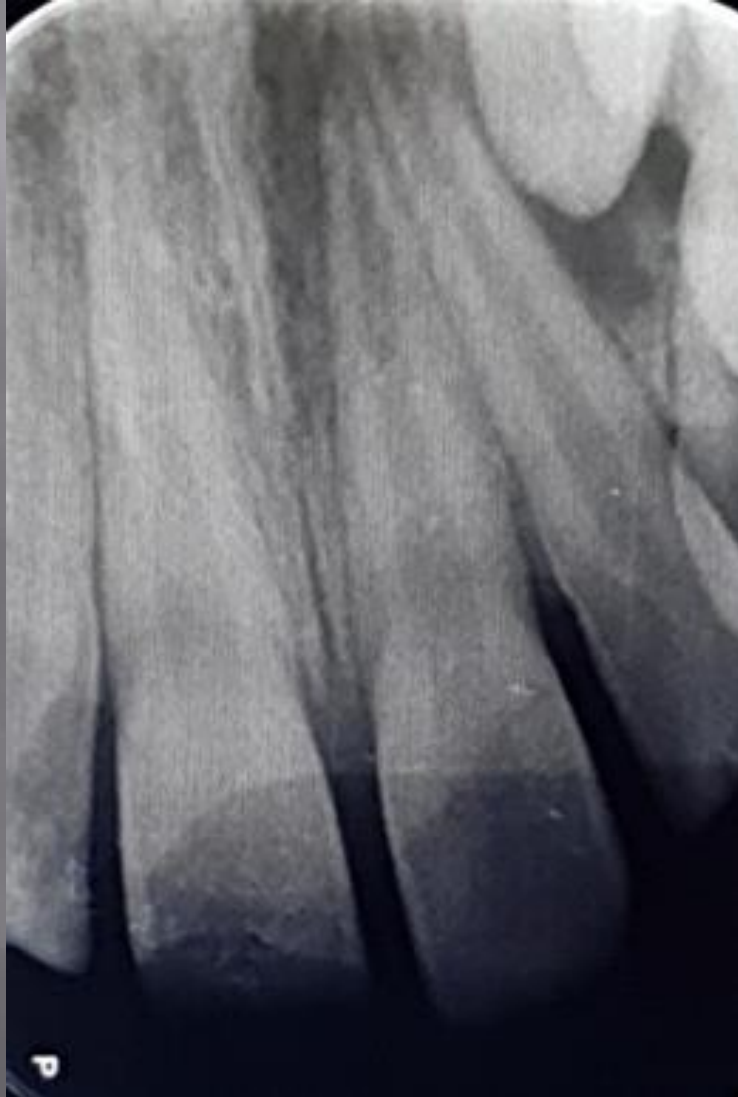C 05-18-2011  
3 month check-up PA

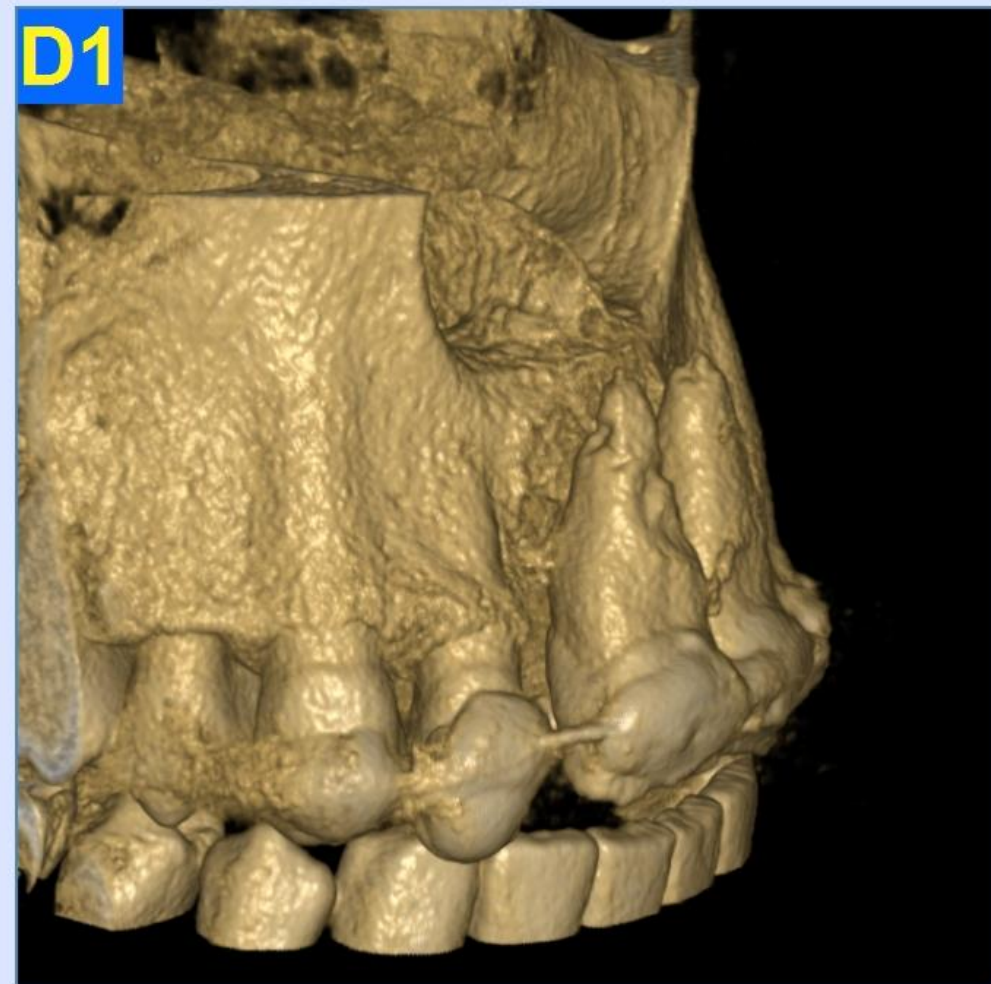
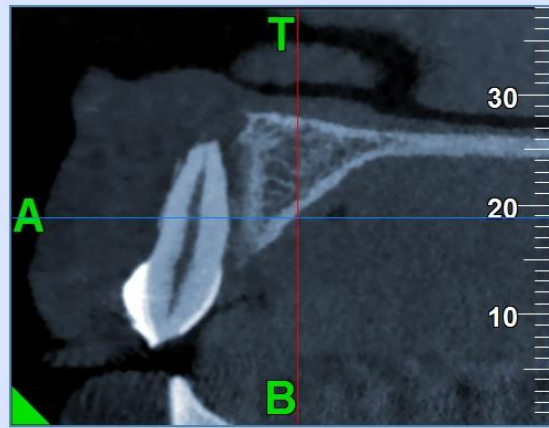
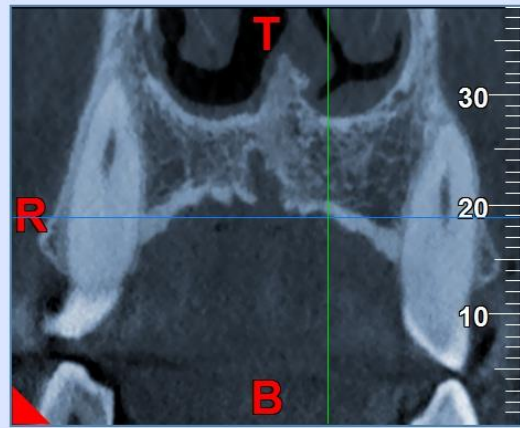
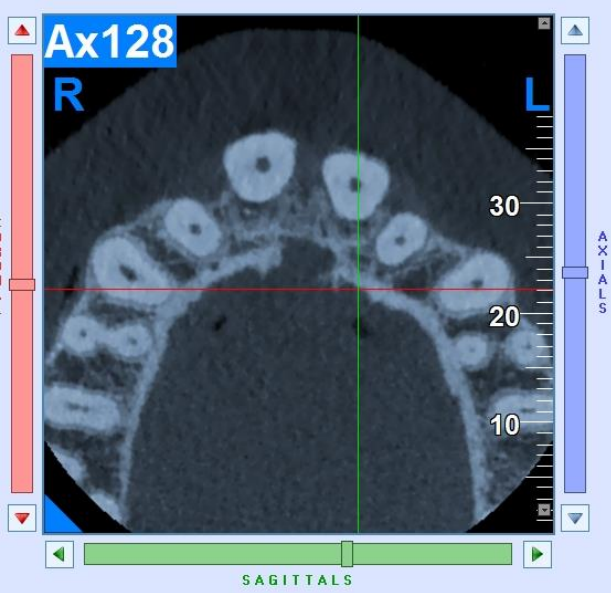
05-18-2011  
3 month check-up corrected sagittal view

D 10-10-2011  
5 month check-up corrected sagittal view

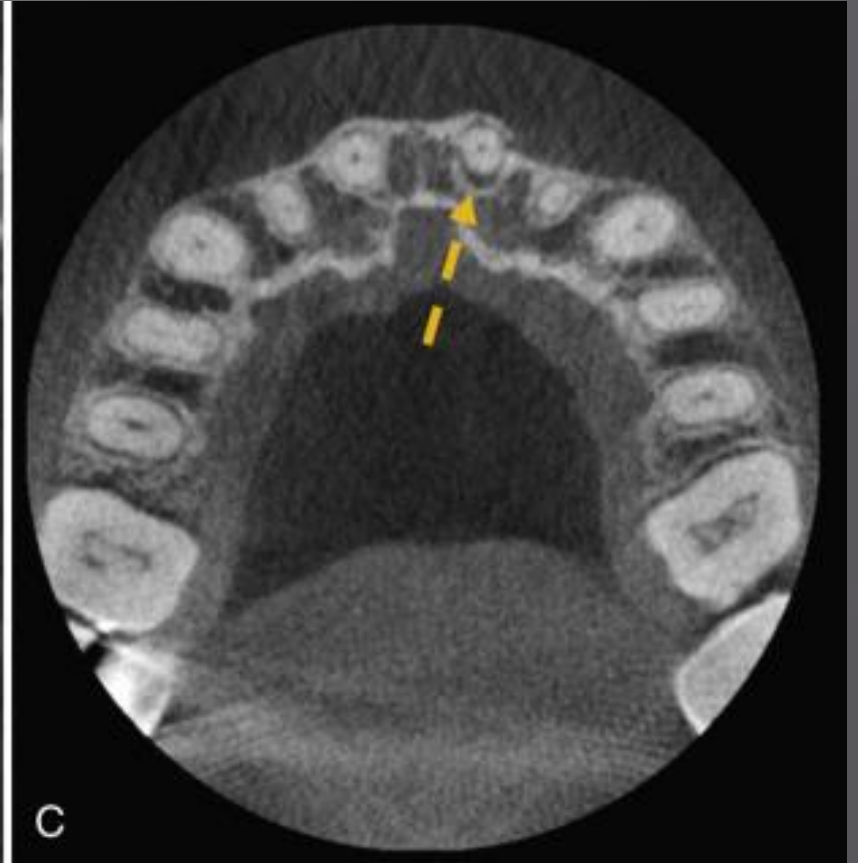
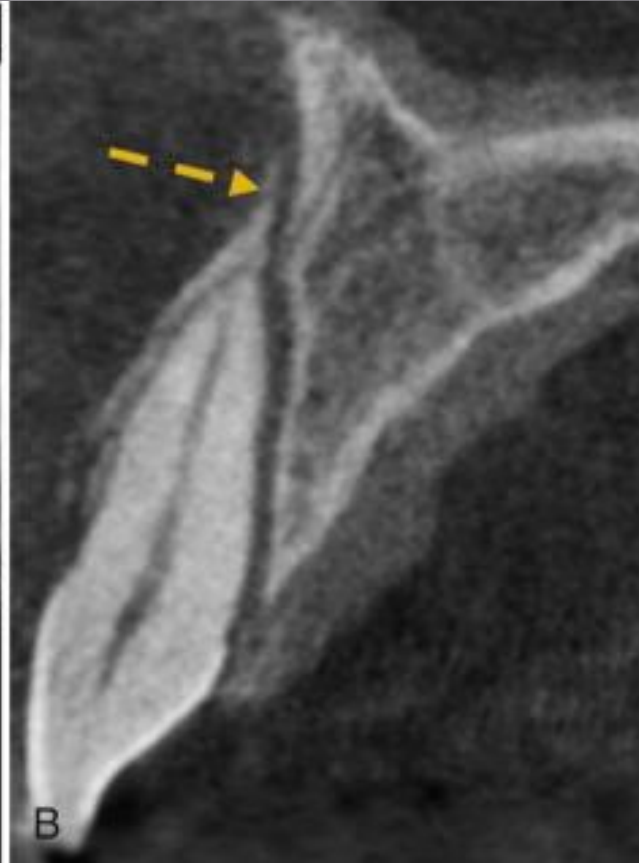
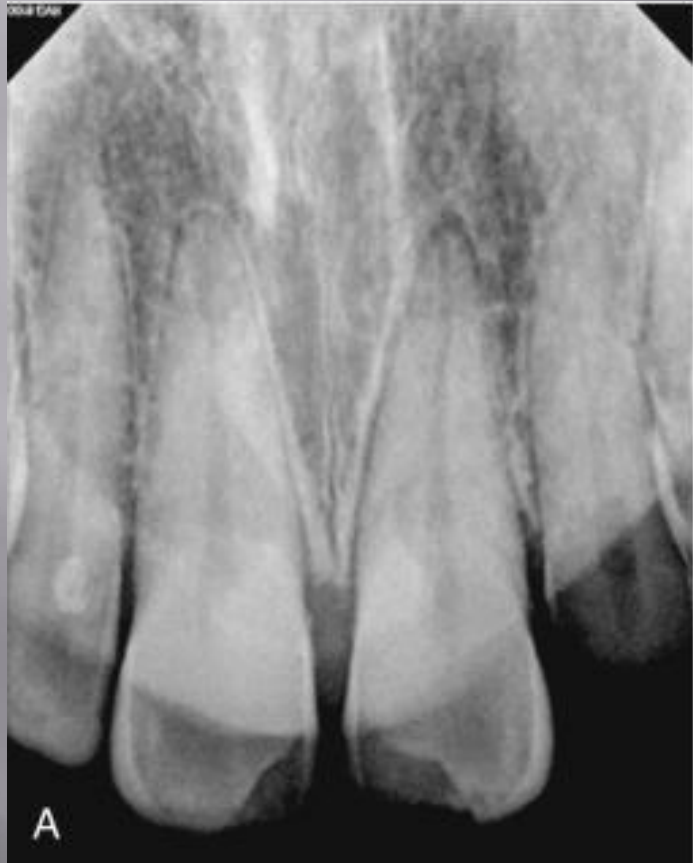# Dentoalveolar Trauma

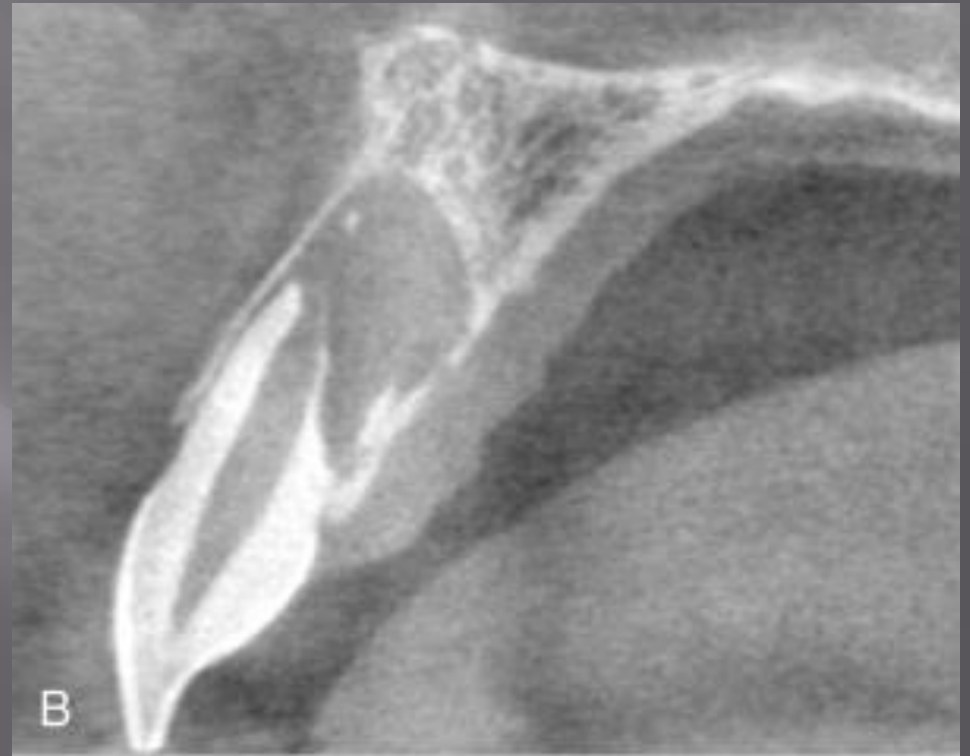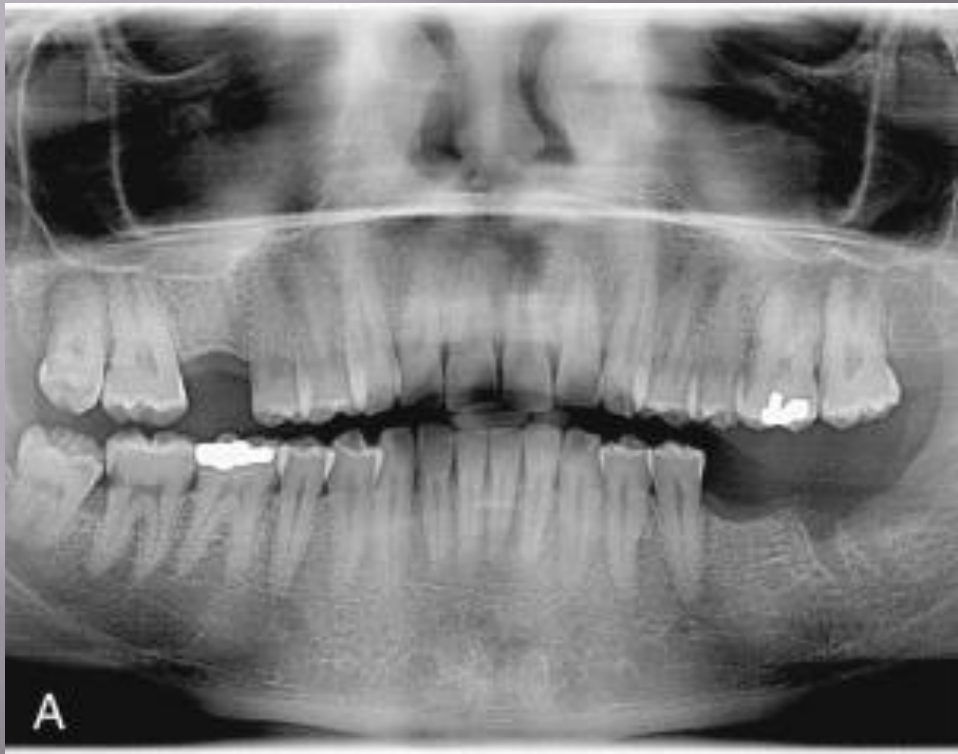# Avulsion

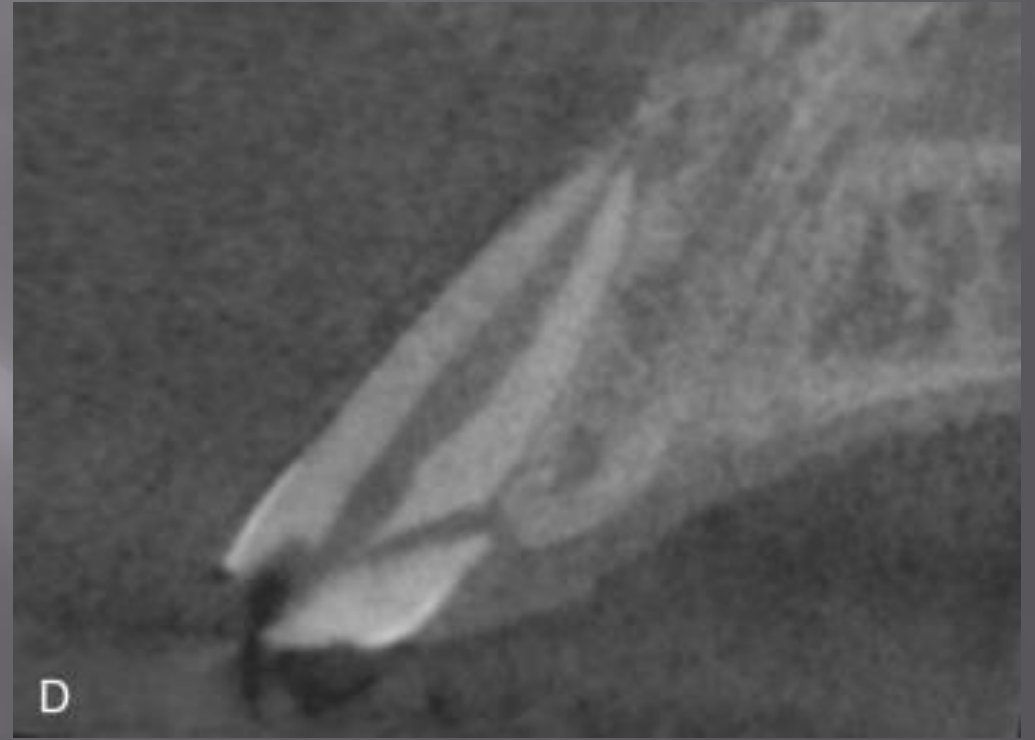
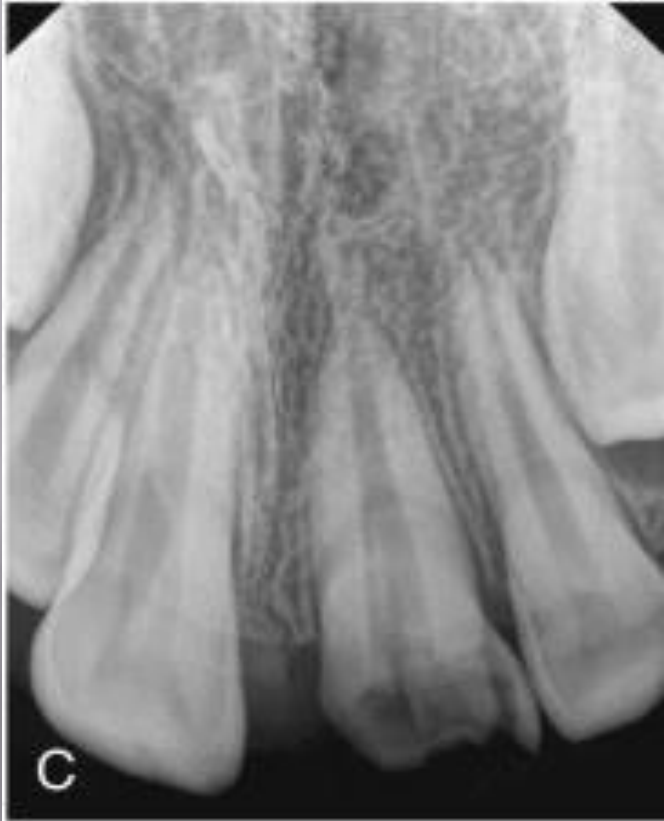











JOINT POSITION STATEMENT OF THE  
AMERICAN ASSOCIATION OF ENDODONTICS  
AND THE AMERICAN ACADEMY OF ORAL  
AND MAXILOFACIAL RADIOLOGY ON THE  
USE OF CONE BEAM COMPUTED  
TOMOGRAPHY IN ENDODONTICS  
(2015 UPDATE)

نفرین لبد بر تو، که آن ساقی چشمست

دردی کش نمنخانه می بر تویر ریا بود

پرورده مریم همم اگر چشم تو می دید

عیسای دگر می شد و غافل ز خدا بود